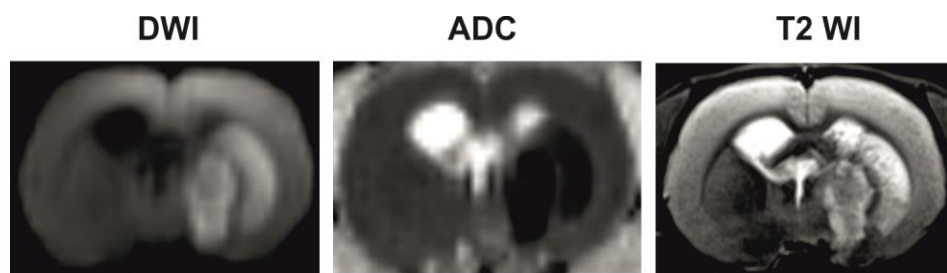


Supplementary Figure S2. MRI of ischemic foci after tMCAO.



DWI with an ADC map and T2 WI scans of the formation of ischemic injury areas with a subcortical localization in the brain of rats at 24 h after tMCAO.