

## KLINIKINIS ATVEJIS

### Sinoorbital gunshot injuries Endoscopic diagnostics and management

Svajūnas Balseris, Dalia Einorienė, Jonas Laimutis Martinkėnas, Rimvydas Toločka  
Vilnius University Emergency Hospital, Lithuania

**Key words:** gunshot injuries; sinuses; orbita; functional endoscopic sinus surgery.

**Summary.** Gunshot injuries to the paranasal sinuses and orbita are uncommon. Their severity depends on missile track in tissues. Such injuries can involve the orbit, paranasal sinuses, or brain. This article reports the main clinical criteria and the aspects of surgical management. Functional endoscopic sinus surgery is the most appropriate technique for removing projectiles left. This article also presents one case of airgun injury to the sphenoid sinus with retained missile that was safely removed using endoscopic procedures.

#### Introduction

**Pathophysiology.** Sinoorbital gunshot wound results in heavy soft tissue and bone lesion and eventually is a life-threatening condition. Wounding capability of bullets is primarily related to velocity (1). High-speed and low-speed lesions are distinguished according to it. Kinetic energy depends more on its velocity than mass (2). The missile track well correlates with bullet structure, size, and velocity. These are also important factors in characterizing the degree of injury. Bullet has a direct, radial blow action and wedged impact as well. They result in formation of depressed, comminuted fractures or a hole defect due to perforative impact. Disintegration of the bone tissue and dislocation of bone fragments induce secondary lesions that can cause more damage than a bullet itself. Depending on the course and trajectory of the missile track sinoorbital gunshot injuries can involve paranasal sinuses, orbita, cranial nerves, or brain (3).

**Epidemiology.** We do not obtain the exact frequency number of gunshot injuries. In USA, more than 33% of intentional and 13.6% of accidental gunshot injuries are to the head and neck region and orbita (4). According to Phoenix Traumatology Center data, about 10% of all incoming patients suffered firearm injury, 95% of which sustained brain lesions. Mortality rate from the gunshot injuries to the head was 60% (5). Isolated sinoorbital ballistic lesions are rare. An extremely high proportion of such injuries result from suicide attempts and accidents in adolescent males (6).

**Diagnostics.** The main and most important diagnostic procedure available is computed tomography (CT) of the head providing accurate diagnostic information. It demonstrates the missile path, bone fragments, localization of retained airgun projectiles, and other lesions as well as the ways of possible removal. CT in several projections reveals an excellent intercourse of projectile and anatomical structures within the sinoorbital region. The coronal CT scan provides a good view of the orbital floor, roof, cribriform plate, paranasal sinuses, and possible intracranial penetration (7). Magnetic resonance imaging (MRI) usually is less informative diagnostic procedure. MRI may not provide adequate imaging of the bones; therefore, its use in sinoorbital gunshot trauma is limited (8).

Angiography in the acute setting of such injuries is a rare diagnostic procedure, unless the vascular laceration is suspected (9). In certain cases, a delayed (after 7–10 days) angiography is indicated for the quite high incidence (approximately 13%) of traumatic fistulas or aneurysms (10). The overall Glasgow Coma Scale (GCS) score is used to evaluate neurological status of the patient and is important for outcome (11). Ocular injury characteristics are evaluated according to the Ocular Trauma Classification System that has been recently brought to practice. It is based on wound character and extent variables, and such standardized assessment seems to predict accurately the visual outcomes in this series (being prognostic for visual outcome). The ocular traumatologic terms are used to describe the nature of eye lesion (12, 13).

With the relatively low rate of these injuries, there are no standard methods of diagnosis and management. Patients with airgun wounds are taken to hospital, and immediate extensive preoperative examination with a combined ophthalmic, neurosurgical and otorhinolaryngological approach is recommended. Proper initial treatment of a patient following missile lesion to the sinoorbital region involves prompt diagnostics and resuscitation according to the recommendations of trauma and brain injury (14, 15). After definitive diagnostic inspection, patients sustaining brain injury with a GCS score of more than 7 require craniotomy. Surgical treatment of patients with a GCS score of 5 to 6 is individual according to bullet track, degree of brain injury, clinical situation, and outcome expected. Surgery is reserved for patients with a GCS score of 3 to 4 with dilated pupillae. In such cases, simple wound débridement and closure followed by conservative therapy is recommended. If a patient is conscious and does not require urgent intracranial operation, the orbital pathology should be managed first. The most important specific variables of ocular injury are following: mechanism of trauma (rupture, penetration, intraocular foreign body, perforation, mixed), visual acuity, pupillary defect, and the location of injury.

After evaluation of visual acuity, local primarily surgical wound management with necrotic tissue, bone fragments and, if possible, airgun projectile removing should be performed. Patients who have orbital wall and paranasal sinus defect undergo operation within 6 months using implants in selected cases. The decision to remove the foreign body should consider possible risks. In the past, external approach was used (16, 17). The same task is possible to accomplish with minimally invasive surgery after endoscopic techniques (functional endoscopic sinus surgery – FESS) were brought to practice in the 1980s. Sinonasal endoscopy is safe, allows excellent visualization, and is the most appropriate method for removing the airgun projectiles in certain cases. Using stereotactic image guidance systems, FESSs can be performed even with greater precision (18). The removal of foreign body using endoscopic techniques is not safe in selected cases. In case of frontal sinus foreign body, an endoscopic technique could be attempted only when a projectile is not imbedded in bone or is adjacent to sinus ostium. Other cases require an external approach with a trepanation necessary to allow insertion of the endoscope. Ethmoid sinus foreign body requires ethmoidotomy (19, 20). Most maxillary sinus projectiles should be accessible with endoscopic antro-

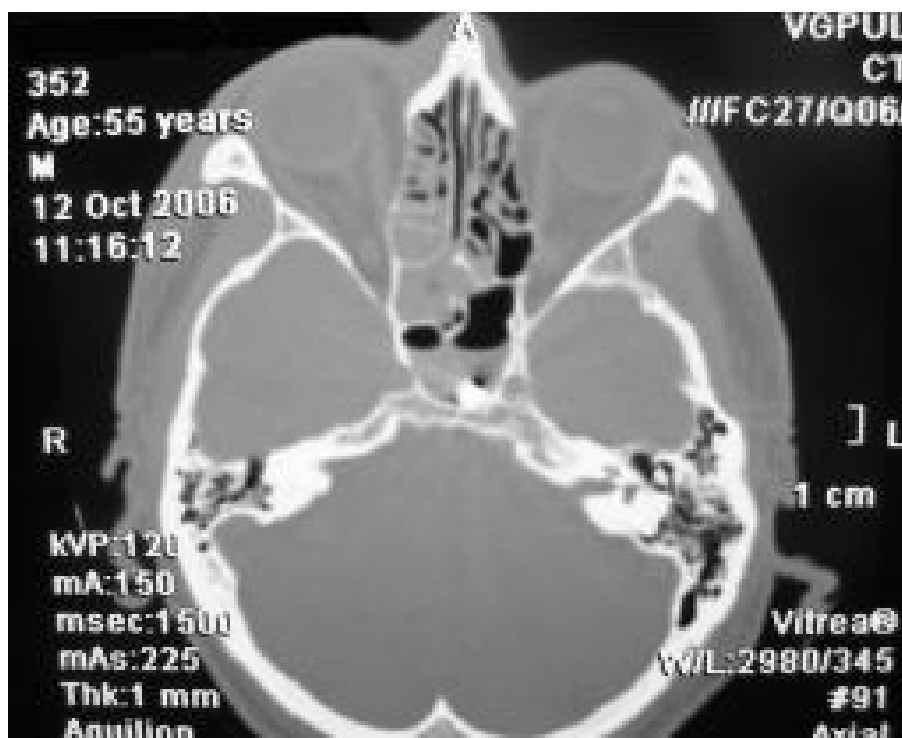
stomy unless imbedded anteriorly – then Caldwell-Luc approach may be necessary. Sometimes an external ethmoidotomy is used to reach to sphenoid sinus and remove the projectile successfully (21). Sphenoid sinus foreign bodies should be approached with special attention for the close proximity of such important structures as optic nerve and internal carotid artery. Skull base projectiles require special vigilance for possible cerebrospinal fluid leakage. Prophylactic antibiotic coverage, initially broad spectrum (cephalosporins 3 g per day and metronidazole 7.5 mg/kg per day), analgesics, and local eye drops are recommended for all patients (3, 8).

Reported long-term sequelae associated with retained bullets in paranasal sinuses include chronic sinusitis, cutaneous fistula, rhinolith formation, meningitis, chronic pain syndrome (6, 18), or even malignancy (22). Long-time observation may increase the risk of poisoning because most retained metallic foreign bodies are made from lead. There have only been a few reports of paranasal foreign bodies observed without sequelae (23).

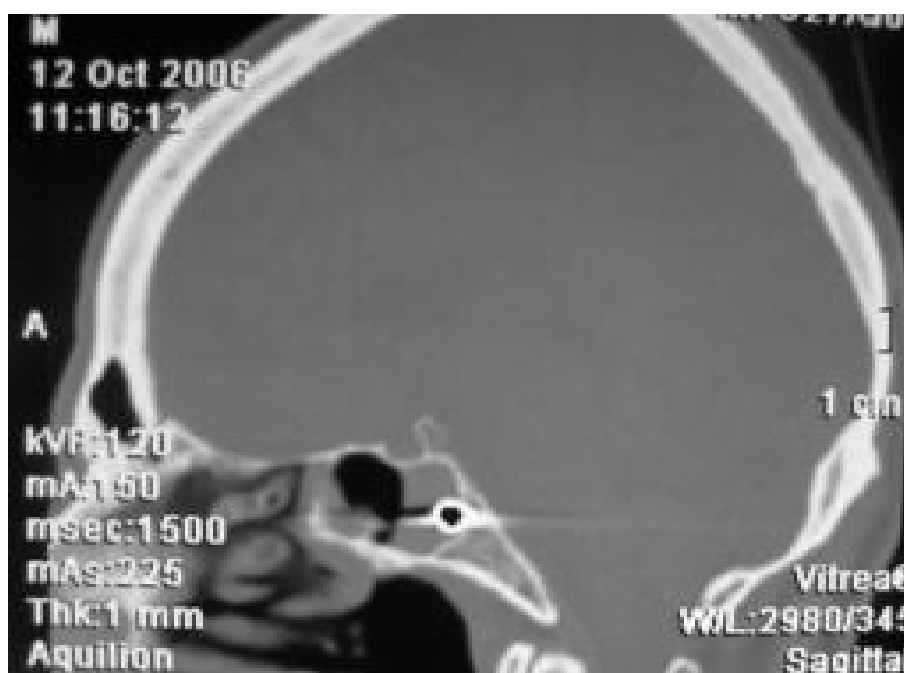### Case report

This article presents one case report to illustrate the appropriate management of patients who had penetrating airgun injuries with retained projectiles in the paranasal sinuses. The important clinical features, indications for operation, its techniques, and potential complications of removal of these foreign bodies from the paranasal sinuses are discussed.

A patient who suffered penetrating sinoorbital firearm injury was taken to Vilnius University Emergency Hospital after suicide attempt. He fired into his right eye from the airgun obtained for self-defense. On admission, he underwent neurosurgical, ophthalmological, and otolaryngological examination. He was neurologically intact with a GCS score of 15; intranasal examination was unremarkable. A small punctate entry wound was seen in the medial corner of the right eye. Axial CT scan with multiplane 3D reconstructions demonstrated the metallic projectile (0.8 cm) lodged in the left sphenoid sinus. Sinus walls were intact. Fluid density content was present in ethmoid cells and sphenoid sinus. Lesion of left medial orbital wall as well as ethmoid sinus could be seen. Right orbita soft tissue injury, exophthalmia, edema of the medial extraocular muscle as well as retroorbital tissue swelling with air insertions were observed. Internal carotid artery and optic nerve were intact. CT scans demonstrated no evidence of intracranial lesions (Figs.



**Fig. 1. Axial CT scan: projectile located in the left sphenoid sinus**



**Fig. 2. Sagittal CT scan: projectile located in inferior posterior corner of the sphenoid sinus**

1 and 2). Visual acuity was not evaluated because of right eye blindness caused by *a. ophthalmica* thrombosis and secondary glaucoma lasting for 2 years.

Gentle surgical débridement of the wound track, removal of gunpowder particles, also eyelid and sclera defect closure using separate sutures under local anes-

thesia were performed during urgent ophthalmology service. Local antibiotic therapy (sol. Gentamycini, sol. Tobrex) was administered. Wounds healed without complications. General condition of the patient was normal, and he was discharged from the ophthalmology clinic.



**Fig. 3. Foreign body (0.8 cm) removed from the sphenoid sinus**

The patient was taken to the operating room 6 weeks later, and retained projectile was removed using endoscopic techniques. Under control of 45° endoscope, left middle conchotomy was performed. After identifying natural ostium of sphenoid sinus, it was enlarged medially and down up to diameter of 10 mm. With endoscopic guidance, optic nerve and carotid were visualized. The missile was lodged in the corner of inferior posterior wall and was removed from the sphenoid sinus with special forceps (Fig. 3). The bleeding during operation was insignificant. Postoperative medical therapy consisted of cefazolin 3 g per day intravenously, nasal drops, and analgetics. The patient tolerated the procedure well and had uneventful postoperative course. He was discharged from the clinic after 4 days of follow-up.

### Discussion

The missile entrance or exit wound may be out of sight in some injuries, and often it is difficult to predict the severity of the injury. An extensive preoperative evaluation of a patient sustaining gunshot sinoorbital trauma with a combined ophthalmic, neurosurgical and otorhinolaryngological approach and CT scanning are strongly recommended (8). The patient who suffered sinoorbital firearm injury was taken to Vilnius University Emergency Hospital after suicide attempt and followed up providing interdisciplinary care.

The literature pertaining to ballistic injuries of paranasal sinuses is not extensive, and this rare entity is generally presented only in case reports. Locations of airgun projectiles vary. Three consecutive cases of airgun injuries to the paranasal sinuses were evaluated

at the University of North Carolina School of Medicine by G. M. Brinson. In the first case, the metallic foreign lodged in the superior aspect of the posterior wall of the maxillary sinus adjacent to the infraorbital canal. In the second case of a patient accidentally shot to the left eyelid, the projectile was present in the Onodi cell region. In the third case, the left eye was injured with a pellet gun. The trajectory of the bullet was identified coursing through the globe, lamina papyracea, and posterior ethmoid cells and lodged in the sphenoid sinus. We conducted a case of one patient who sustained the same pathology. He had a retained projectile in sphenoid sinus as well.

The main diagnostic procedure available is CT of the head providing accurate information about the intercourse of the foreign body and surrounding anatomical structures (3, 8). In certain series, MRI is indicated, although it is less informative and is contraindicated because of the potential risk for migration and further injury in case of intracranial foreign metallic body (8). Angiography in the initial evaluation is an uncommon diagnostic procedure unless a vascular laceration is suspected (9). Diagnostic examination revealed no neurosurgical pathology and showed neurological function to be intact. CT scans demonstrated the projectile present in the inferior posterior corner of the left sphenoid sinus.

Surgical management in cases of sinoorbital gunshot injury is subdivided to urgent ophthalmological service and planned otolaryngological aid (8). In our case, the patient underwent urgent ophthalmologic treatment, and after 6 weeks, an endoscopic removal of the foreign body was performed. Sinoorbital gunshot injuries should be treated using conventional and endoscopic techniques (16, 17, 21). Nevertheless, according to Brinson, endoscopic surgery is the safest, minimally invasive, and therefore the most preferred management in such series (18). Endoscopic techniques were also successful in our case. The removal of foreign body was accomplished without complications and provided the desired outcome.

### Acknowledgement

Authors give special thanks to Dr. R. Vaičaitienė (Clinic of Ophthalmology, Vilnius University Emergency Hospital) and Dr. R. Kvaščevičius (Clinic of Neurosurgery, Vilnius University Emergency Hospital) for cooperation.

## Sinusų ir orbitos šautiniai sužalojimai. Endoskopinė diagnostika ir gydymas

Svajūnas Balseris, Dalia Einorienė, Jonas Laimutis Martinkėnas, Rimvydas Toločka  
Vilniaus greitosios pagalbos universitetinė ligoninė

**Raktažodžiai:** šautiniai sužalojimai, sinusai, akiduobė, funkcinė endoskopinė sinusų chirurgija.

**Santrauka.** Sinusų ir orbitos šautiniai sužalojimai yra reti. Jų sunkumas priklauso nuo kulkos trajektorijos audiniuose. Gali būti pažeista akiduobė, sinusai, smegenys. Straipsnyje aptariami svarbiausi sinusų ir orbitos šautiniai sužalojimų klinikiniai požymiai, chirurginio gydymo aspektai. Funkcinė endoskopinė sinusų chirurgija yra tausojantis ir mažiausiai traumuojantis metodas šalinant svetimkūnius, esančius sinusuose. Aprašomas vienas klinikinis atvejis, kai pleištiname antyje buvo likęs svetimkūnis (kulka). Naudojant endoskopinę techniką, kulka buvo sėkmingai pašalinta.

Adresas susirašinėti: D. Einorienė, Vilniaus greitosios pagalbos universitetinės ligoninės  
Ausų, nosies ir gerklės ligų klinika, Šiltnamių 29, 04130 Vilnius. El. paštas: dalia.ent@gmail.com

### References

1. Owen-Smith MS. High velocity missile wounds. London: Edward Arnold, Ltd; 1981. p. 21-32.
2. Cary ME, Sarna GS, Farrell JB. Experimental missile wound to the brain. J Neurosurg 1989;71:754-64.
3. Wilkins RH, Rengachary SS. Neurosurgery. Vol. VIII. Lippincott Williams & Wilkins; 1982. p. 2813-9.
4. Sinauer N, Annest JL, Mercy JA. Unintentional, nonfatal firearm-related injuries: a preventable public health burden. JAMA 1996;275:1740-3.
5. Petersen S, Bowlby KJ. Trauma report. Phoenix, AZ: St. Josephs Hospital and Medical Center; 1997.
6. Bowen DI, Magauran DM. Ocular injuries caused by airgun pellets: an analysis of 105 cases. BMJ 1973;1:333-7.
7. Dunya IM, Rubin PAD, Shore JW. Penetrating orbital trauma. Int Ophthalmol Clin 1995;35:25-36.
8. Gönül E, Erdoğan E, Taşar M, Yetişer S, Akay KM, Düz B, et al. Penetrating orbitocranial gunshot injuries. Surg Neurol 2005;63:24-31.
9. Miller CF, Brodkey JS, Colombi BJ. The danger of intracranial wood. Surg Neurol 1977;7:95-103.
10. Haddad FS, Haddad GF, Taha J. Traumatic intracranial aneurysms caused by missiles: their presentation and management. Neurosurgery 1991;28:1-7.
11. Erdogan E, Gonul E, Seber N. Craniocerebral gunshot wounds. Neurosurg Q 2002;12:1-18.
12. Kuhn F, Morris R, Witherspoon D, Heiman K, Jeffers JB, Treister G. A standardized classification of ocular trauma. Ophthalmology 1996;103:240-3.
13. Sobaci G, Mutlu FM, Bayer A, Karagul S, Yildirim E. Deadly weapon-related open-globe injuries: outcome assessment by the Ocular Trauma Classification System. Am J Ophthalmol 2000;129(1):47-53.
14. American College of Surgeons Committee on Trauma: resources for optimal care of the injured patient. Chicago: Committee on Trauma; 1990.
15. Bullock R, Chesnut RM, Clifton G, Ghajar J, Marion DW, Narayan RK, et al. Guidelines for the management of severe head injury. New York: Brain Injury Foundation; 1995.
16. Harris WD. Large sphenoid sinus foreign body. Arch Otolaryngol Head Neck Surg 1968;88:436-8.
17. Sinha SN. Foreign body in the maxillary sinus. J Laryngol Otol 1968;82:473-6.
18. Brinson GM, Brent A, Yarbrough WG. Endoscopic management of retained airgun projectiles in the paranasal sinuses. Otolaryngology Head Neck Surg 2004;130(1):25-30.
19. Donald PG, Gadre AK. Neuralgia-like symptoms in a patient with an airgun pellet in the ethmoid sinus: a case report. J Laryngol Otol 1995;109:646-9.
20. Murthy PS, Sahota JS, Nayak DR, Balakrishnan R, Hazarika P. Foreign body in the ethmoid sinus. Int J Oral Maxillofac Surg 1994;23:74-5.
21. O'Connell JE, Turner NO, Pahor AL. Airgun pellets in the sinuses. J Laryngol Otol 1995;109:1097-100.
22. Ben-David J, Podoshin L, Bartal AH. Plasmocytoma arising in the vicinity of a foreign body in the nasal cavity. Laryngoscope 1981;91:1150-4.
23. Lubianca Neto JF, Mauri M, Machado JR, Ceccon A, Paim da Cunha C. Air gun dart injury in paranasal sinuses left alone. Int J Pediatr Otorhinolaryngol 2000;52:173-6.

Received 6 March 2008, accepted 15 April 2008  
Straipsnis gautas 2008 03 06, priimtas 2008 04 15