

KLINIKINIS ATVEJIS

Mucinous adenocarcinoma arising in an anorectal fistula

Linas Venclauskas, Žilvinas Saladžinskas, Algimantas Tamelis,
Darius Pranys¹, Dainius Pavalkis

Department of Surgery, ¹Department of Pathological Anatomy, Kaunas University of Medicine, Lithuania

Key words: mucinous adenocarcinoma; anorectal fistula.

Summary. Mucinous adenocarcinoma in association with chronic anal fistula is a rare case in clinical practice.

The aim of this article was to report a rare case of anal gland mucinous adenocarcinoma in a patient who was treated in the Hospital of Kaunas University of Medicine.

Case report. A 70-year-old male was treated for anorectal fistula in the surgical department. Four operations were performed for perineal abscess during the period of 15 years. During the period of 15 years, the patient complained of purulent secretion from the perineal abscess. After the last operation, anorectal fistula developed. Multiple biopsies and scrapings of the fistulous track were taken for histological examination. Histological examination revealed mucinous adenocarcinoma, G2. Subsequently, the patient underwent endoanal ultrasound, computed tomography scan, and colonoscopy. The computed tomography scan did not show pathology in the abdomen, but showed soft tissue induration at the site of anorectal fistula. Colonoscopy investigation did not show any pathology in the rectum and bowels. Endoanal ultrasound findings showed soft tissue induration at the site of anorectal fistula, no tumor in the rectum wall. The patient underwent abdominoperineal resection. Histological examination after abdominoperineal resection revealed anal duct mucinous adenocarcinoma pT2 N0 L0 V0 R0, G2. Metastases to the mesenteric lymph nodes were not detected. On the eighth day after abdominoperineal resection, the patient was discharged from the hospital for follow-up.

Summary. Mucinous adenocarcinoma in anorectal fistula is a rare condition. If surgical treatment for perineal abscess or anorectal fistula is not successful for a long time, mucinous adenocarcinoma should be suspected.

Introduction

Mucinous adenocarcinoma in association with chronic anal fistula is a rare case in the clinical practice. Sometimes it is very difficult to diagnose this disease, and it requires a long time and knowledge.

The aim of this article was to report a rare case of anal gland mucinous adenocarcinoma in a patient who was treated in the Hospital of Kaunas of University Medicine.

Case report

A 70-year-old male was treated for anorectal fistula in the surgical department. He complained of anal pain, perineal induration, and the secretion of pus from the perineal area and the rectum (Fig. 1). Fifteen years ago, he had undergone an operation for perineal

abscess. After the first operation, four operations were performed for perineal abscess during the period of 15 years. The last surgical treatment for perineal abscess was performed 3 months before hospitalization to the Clinic of Surgery. During the period of 15 years, the patient complained of purulent secretion from the perineal abscess. After the last operation, anorectal fistula developed. Multiple biopsies and scrapings of the fistulous track were taken for histological investigation. Histological examination revealed mucinous adenocarcinoma, G2. Subsequently, the patient underwent endoanal ultrasound, computed tomography (CT) scan, and colonoscopy. The CT scan did not show pathology in the abdomen, but showed soft tissue induration at the site of anorectal fistula. Colonoscopy did not show any pathology in the rectum

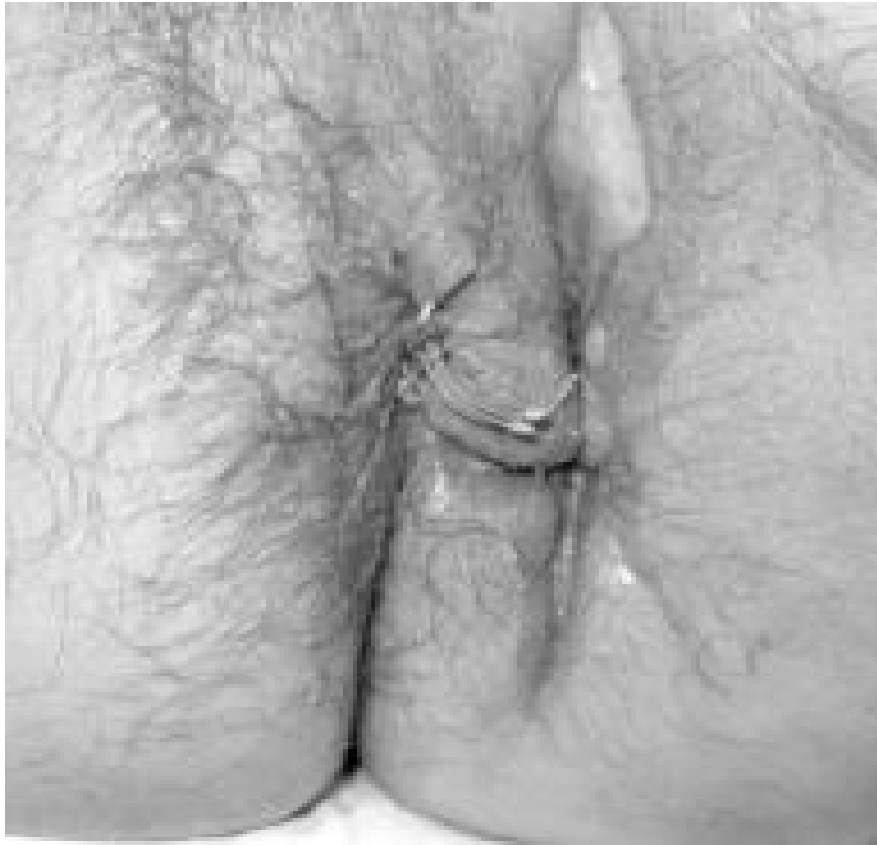

Fig. 1. Before the last operation (abdominoperineal resection)

Soft tissue scar and induration in the left side of the perineum and cutting seton in the fistula canal.

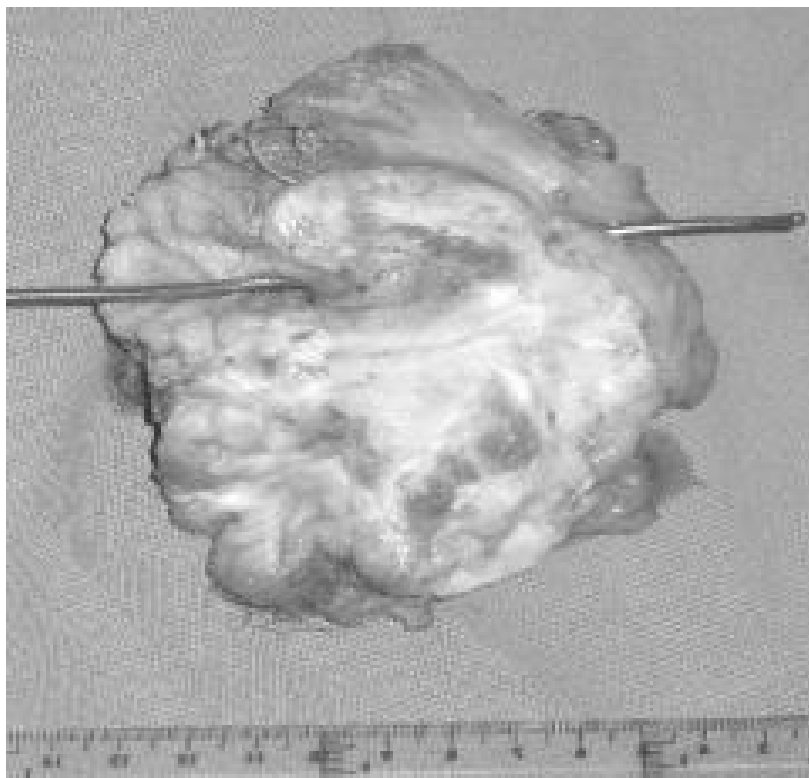

Fig. 2. Rectum with mucinous adenocarcinoma

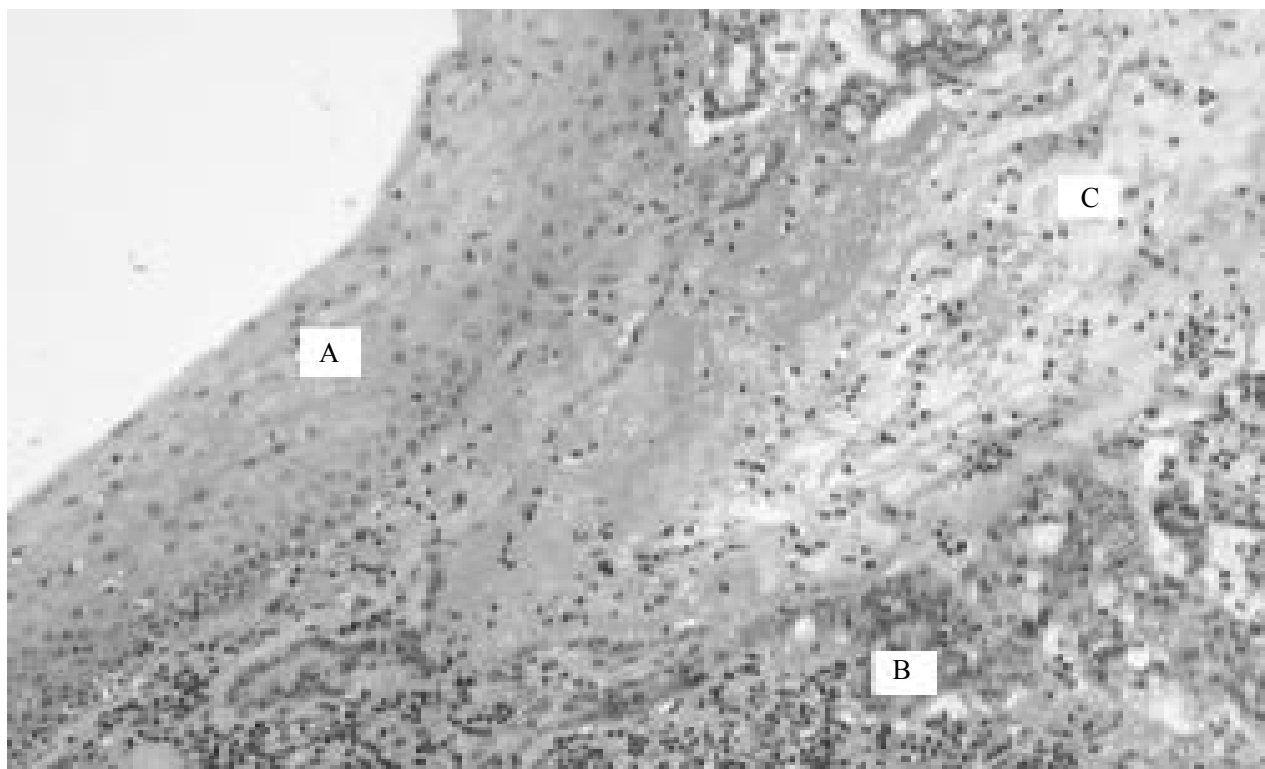


Fig. 3. Histological examination (hematoxylin-eosin)

A – epithelium of the rectum; B – tumorous glands; C – mucus.

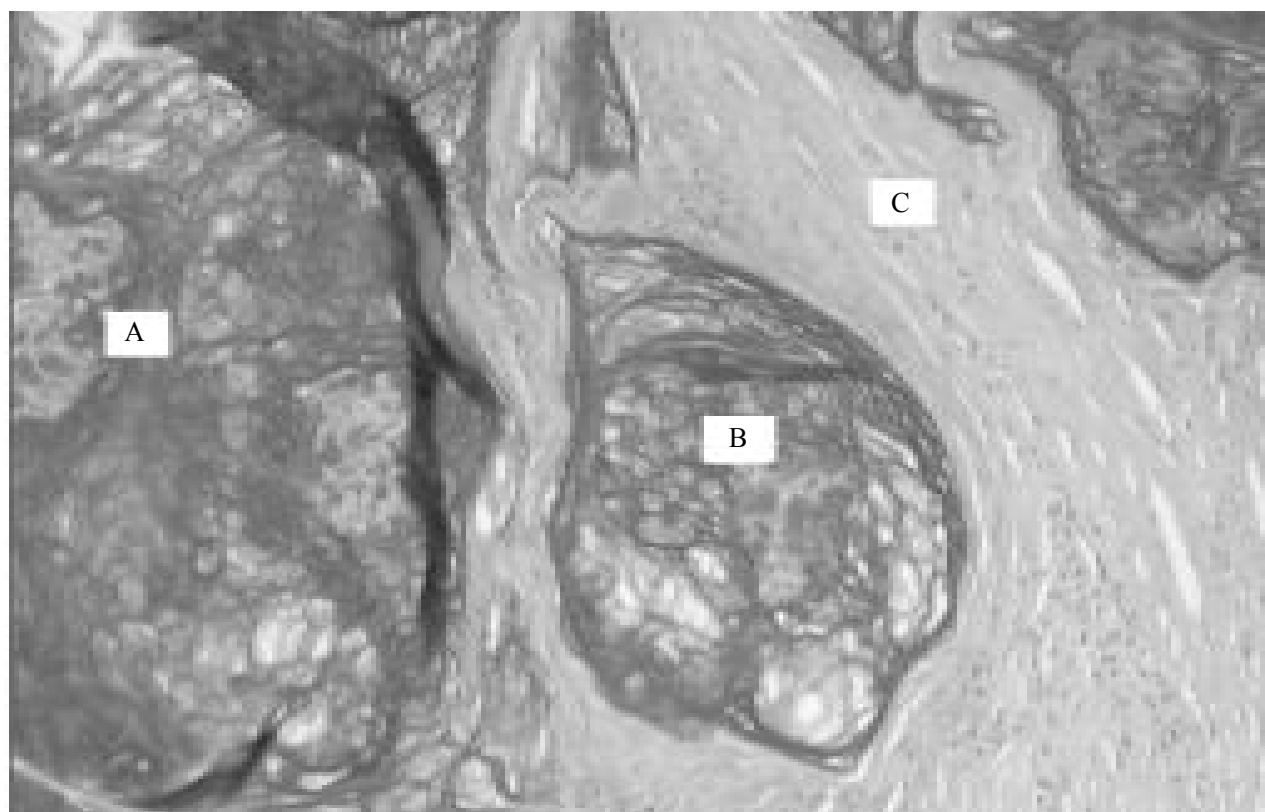


Fig. 4. Histological examination (mucicarmine)

A and B – mucus with malignant cell groups; C – stroma.

and bowels. Endoanal ultrasound investigation showed soft tissue induration at the site of anorectal fistula, no tumor in the rectum wall. The patient underwent abdominoperineal resection (APR) (Fig. 2). Histological conclusion after abdominoperineal resection was anal duct mucinous adenocarcinoma pT2 N0 L0 V0 R0, G2 (Fig. 3, 4). Metastases to the mesenteric lymph nodes were not detected. On the eight day after APR, the patient was discharged from the hospital for follow-up.

Discussion

Adenocarcinoma in association with chronic anal fistula is a rare case resulting in severe problems concerning diagnosis and treatment. This was a case of mucinous adenocarcinoma arising in a long-standing perineal abscess and fistula development after multiple operations. With a long history of mucinous discharge, pain and perianal induration, the patient underwent a biopsy of the external opening of the fistula that showed infiltrating adenocarcinoma. The incidence of this malignancy is low. The tissues from which the disorder originates are the glands of the anal duct. The features that differentiate this tumor from the usual rectal carcinoma are prominent ductal structures, abundant mucinous production with organized mucinous pools, and infiltration into the perirectal soft tissue (1, 2). The study about the origin of mucinous adenocarcinoma in anorectal fistula was performed by Jones and Morson (3). The data of this study suggest that the fistulous tracks are congenital duplications of the lower end of the hind gut lined by rectal mucosa that is prone to malignant change to mucinous adenocarcinoma (3). Other origins of the mucinous adenocarcinoma in anorectal fistula can be chronic (pan) colitis, Crohn's disease with high inflammatory activity, and the persistence of chronic fistulas and stenosis that seem to trigger malignant transformation (4). Anal fistula may also arise from infected anal glands, and it may be speculated that chronic inflammation could also induce anal gland epithelium to undergo neoplastic change (5–8).

Fenger and Filipe were the first to report that anal gland carcinomas contain mucin showing a characteristic scarcity or absence of *O*-acetylated sialic acid. A reduction of these sugar groups has also been described in inflammatory bowel disease and in colorectal adenocarcinomas (5).

The diagnosis of anal gland mucinous adenocarcinoma is difficult. The patients can complain of anal pain, rectal bleeding, and the secretion of pus from the perineal area. Some authors report that pain and bleeding are present in all cases (9). The examination

of the patient reveals anorectal structure, perianal induration, anorectal fistula, and pus in the perineum. American surgeons performed a study (52 cases) showing that the predominant symptoms of malignancy were anal pain (58%), rectal bleeding (4%), and the presence of perianal mass (37%). Fifty-four percent of patients had a fistula, with the incidence rates of fistula significantly higher in males. Metastases that may be inguinal, pelvic, or hepatic are present during the diagnosis in 13.5% of patients (10). The metastases often are findings in the superficial inguinal or in the retrorectal lymph nodes (8, 9, 11). In cases of a prolonged (persisting for a number of years) persistence of chronic fistula or anorectal fistula with chronic inflammatory diseases such as colitis or Crohn's disease, it is necessary to suspect anal gland carcinoma. Biopsies of the fistulous tracks or the perineal mass are necessary to establish the diagnosis. An accurate staging of the neoplasm, using endoanal ultrasound, MR or CT scans, is needed to plan the appropriate treatment (1, 8, 12). MRI is the best investigation of anal gland mucinous adenocarcinoma. Mucinous adenocarcinoma arising in fistula-in-ano is a rare entity but can be diagnosed by the following three characteristic MRI findings: markedly hyperintense fluid on T2-weighted images, enhancing solid components, and a fistula between the mass and the anus (8).

The main treatment of anal gland mucinous adenocarcinoma is APR with or without neoadjuvant chemoradiotherapy. The APR has to be performed with wide local excision of the perirectal soft tissue (1, 6, 10–15). Some authors indicate that the prognosis after surgical mucinous adenocarcinoma treatment is good if the condition is diagnosed and treated early. In these cases, the patients do not need adjuvant chemoradiotherapy. Follow-up of the patient is sufficient, because the role of subsequent radiation therapy and/or chemotherapy has not been defined yet (3, 6, 10, 15). The prognosis depends on the stage of the tumor. At presentation, if a tumor is larger than 5 cm in diameter, in 80% of the cases, the prognosis is poor (11). Other authors state that the prognosis of this disease is poor; therefore, neoadjuvant chemotherapy and radiotherapy should be applied for patients after APR, since it increases the median survival up to 3 years (1, 7, 9, 11).

Summary

Mucinous adenocarcinoma in anorectal fistula is a rare condition. If surgical treatment for perineal abscess or anorectal fistula is not successful for a long time, mucinous adenocarcinoma should be suspected.

In case of long-standing anorectal fistula and/or suppuration of the noncrypto-glandular origin, biopsy should be performed before definitive treatment.

The only option for radical treatment is abdomino-

perineal resection with or without radio/chemotherapy according to TNM stage. The first choice to diagnose mucinous adenocarcinoma is magnetic resonance imaging.

Muciną išskirianti adenokarcinoma, suformavusi išangės – tiesiosios žarnos fistulę

Linas Venclauskas, Žilvinas Saladžinskas, Algimantas Tamelis, Darius Pranys¹, Dainius Pavalkis

Kauno medicinos universiteto Chirurgijos klinika, ¹Patologinės anatomijos klinika

Raktažodžiai: muciną išskirianti adenokarcinoma, išangės – tiesiosios žarnos fistulė.

Santrauka. Muciną išskirianti adenokarcinoma, suformavusi išangės – tiesiosios žarnos fistulę, yra retas ligos atvejis klinikinėje praktikoje.

Tyrimo tikslas. Aptarti klinikinį atvejį paciento, kuris gydytas Kauno medicinos universiteto klinikose dėl išangės liaukų muciną išskiriančios adenokarcinomos.

Klinikinis atvejis. 70 metų vyras gydytas Chirurgijos klinikoje dėl išangės – tiesiosios žarnos fistulės. 15 metų laikotarpiu jam buvo atliktos keturios operacijos dėl išangės pūlinio. Visą šį laikotarpį pacientas skundėsi pūliavimu išangės srityje. Po paskutinės operacijos susiformavo išangės – tiesiosios žarnos fistulė. Iš fistulės kanalo buvo paimta audinių nuogrاندų histologiniam ištyrimui. Histologinio tyrimo atsakymas: muciną išskirianti adenokarcinoma G2. Pacientui atlikti tyrimai: dubens kompiuterinė tomografija, kolonoskopija bei endoskopinis ultragarsinis tiesiosios žarnos tyrimas. Kolonoskopijos metu organinės patologijos nenustatyta. Dubens kompiuterinės tomografijos ir endoskopinio ultragarsinio tiesiosios žarnos tyrimų metu nustatyta minkštųjų audinių infiltracija išangės – tiesiosios žarnos srityje. Pacientas operuotas. Atlikta tiesiosios žarnos ekstirpacija. Histologinis pašalintos tiesiosios žarnos atsakymas – išangės liaukų muciną išskirianti adenokarcinoma pT2 N0 L0 V0 R0, G2. Naviko išplitimo į pasaito limfmazgius nenustatyta. Aštuntąją pooperacinę dieną pacientas išrašytas į namus. Papildomo gydymo neskirta.

Apibendrinimas. Muciną išskirianti adenokarcinoma, suformavusi išangės – tiesiosios žarnos fistulę, yra reta ligos klinikinė forma. Jei išangės – tiesiosios žarnos pūlinio ar fistulės chirurginis gydymas ilgą laiką yra neveiksmingas, reikėtų pagalvoti apie išangės liaukų muciną išskiriančią adenokarcinomą.

Adresas susirašinėti: L. Venclauskas, KMU Chirurgijos klinika, Eivenių 2, 50009 Kaunas,
El. paštas: linasvenclauskasg@yahoo.com

References

1. Navarra G, Ascanelli S, Turini A, Lanza G, Gafa R, Tonini G. Mucinous adenocarcinoma in chronic anorectal fistula. *Chir Ital* 1999;51(5):413-6.
2. Perkowski PE, Sorrells DL, Evans JT, Nopajaroonsri C, Johnson LW. Anal duct carcinoma: case report and review of the literature. *Am Surg* 2000;66(12):1149-52.
3. Jones EA, Morson BC. Mucinous adenocarcinoma in anorectal fistulae. *Histopathology* 1984;8(2):279-92.
4. Winkler R, Wittmer A, Heusermann U. Cancer and Crohn's disease. *Z Gastroenterol* 2002;40:569-76.
5. Wong NACS, Shirazi T, Hamer-Hodges DW, Corfield AP, Lessells AM. Adenocarcinoma arising within a Crohn's-related anorectal fistula: a form of anal gland carcinoma? *Histopathology* 2002;40(3):302-4.
6. Papapolychiadis C, Kaimakis D, Giannoulis K, Berovalis P, Karamanlis E, Haritanti A, et al. A case of mucinous adenocarcinoma arising in long-standing multiple perianal and presacral fistulas. *Tech Coloproctol* 2004;8:s138-40.
7. Mates IN, Dinu D, Radulescu G, Iosif C. Infiltrating mucinous carcinoma developed on chronic anal fistula; diagnostic and surgical difficulties. *Chirurgia (Bucur)* 2003;98(5):459-64.
8. Fujimoto H, Ikeda M, Shimofusa R, Terauchi M, Eguchi M. Mucinous adenocarcinoma arising from fistula-in-ano: findings on MRI. *Eur Radiol* 2003;13:2053-4.
9. Anthony T, Simmang C, Lee EL, Turnage RH. Perianal mucinous adenocarcinoma. *J Surg Oncol* 1997;64(3):218-21.
10. Abel ME, Chiu YS, Russell TR, Volpe PA. Adenocarcinoma of the anal glands. Results of a survey. *Dis Colon Rectum* 1993;36(4):383-7.
11. Marti L, Nussbaumer P, Breitbach T, Hollinger A. Perianal mucinous adenocarcinoma. A further reason for histological study of anal fistula or anorectal abscess. *Chirurg* 2001;72(5):573-7.
12. Nelson RL, Prasad ML, Abcarian H. Anal carcinoma presenting as a perirectal abscess or fistula. *Arch Surg* 1985;120(5):632-5.
13. Katayama Y, Ihara K, Kimura M, Nagai K, Kawaguchi T. Carcinoma in anorectal fistula of rectal mucosal origin. *Acta Pathol Jpn* 1984;34(3):649-54.
14. Lee SH, Zucker M, Sato T. Primary adenocarcinoma of an anal gland with secondary perianal fistulas. *Hum Pathol* 1981;12(11):1034-7.
15. Cirocchi R, Covarelli P, Gulla N, Fabbri B, Bisacci R, Fabbri C, et al. Adenocarcinoma arising from a recurrent fistula-in-ano. *Ann Ital Chir* 1999;70(5):771-4.

Received 19 February 2008, accepted 2 December 2008
Straipsnis gautas 2008 02 19, priimtas 2008 12 02