

Stargardt Disease Caused by a Rare Combination of Double Homozygous Mutations

Danielius Serapinas, Viltautė Obrikytė, Raimundas Sakalauskas

Department of Pulmonology and Immunology, Medical Academy, Lithuanian University of Health Sciences, Lithuania

Key Words: *ABCA₄; mutation; Stargardt disease.*

Summary. *Stargardt disease is a juvenile macular degeneration most often inherited in an autosomal recessive pattern, characterized by decreased vision in the first 2 decades of life. This report presents a clinical case of Stargardt disease: a 10-year-old female patient complained of blurry vision, and in a 4-year period, her visual acuity was reduced from OD=0.3 and OS=0.3 to OD=0.08 and OS=0.1, respectively. A genetic analysis revealed a rare combination of 2 homozygous recessive mutations in the ABCA₄ gene, which caused Stargardt disease. The presence of different genetic mechanisms leading to a severe disease phenotype can challenge molecular geneticists, ophthalmologists, and genetic counselors.*

Introduction

Stargardt disease (STGD1, MIM number 248200) is the most common hereditary macular dystrophy affecting children, with a prevalence of approximately 1:10000 (1). The vast majority of cases are autosomal recessive, but some dominant pedigrees have been reported (1). An adenosine triphosphate-binding cassette, the *ABCR* gene (now called *ABCA₄*), has been identified as the causative gene. This photoreceptor-specific gene is localized to chromosome 1p21-22 (2, 3). Biochemical studies and analysis of *ABCA₄* knockout mice and patients with Stargardt disease have implicated *ABCA₄* as a lipid transporter that facilitates the removal of potentially toxic retinal compounds from photoreceptors following photoexcitation (4).

Affected individuals typically experience a significant loss of central vision with a marked reduction in visual acuity in their first or second decade of life. A progressive decrease in visual acuity generally occurs throughout life with values reaching 0.1 or worse in the final stages of the disease. Patients with Stargardt disease also show a delay in dark adaptation and a variable loss in color vision (4).

An accumulation of discrete “pisciform” flecks at the level of the retinal pigment epithelium (RPE) is a hallmark of the disease. The distribution of the flecks and the time of their appearance can vary, but the flecks seen in Stargardt disease are found mostly at the posterior pole and the macula. Fundus changes may include a polychromatic sheen of the macula referred to as a “beaten-bronze” appearance; a “bull’s eye” macular appearance may also occur (3).

A “dark” or “silent” choroid may be seen with fluorescein angiography (FA) in 70% of cases. The flecks themselves do not stain with fluorescein. In Stargardt disease, the retina exhibits autofluorescence, an index of the lipofuscin content in the RPE (5, 6). At the beginning of the disease, an electroretinogram (ERG) usually shows no abnormalities. In case of the advanced disease and extensive RPE changes, the abnormal Arden ratio can be seen on the electro-oculogram.

Atrophic changes in the photoreceptors and a disruption of the foveal RPE are demonstrated on ultrahigh resolution optical coherence tomography (OCT). Lipofuscin deposits can be detected within the parafoveal RPE. Determining the status of the photoreceptor layer on OCT may provide an assessment of the central visual function (6).

A histochemical analysis of the donor eyes of a deceased patient with Stargardt disease revealed a significant loss of photoreceptor cells and an excessive accumulation of lipofuscin deposits in the RPE cells. Lipofuscin deposits are composed of a heterogeneous mixture of oxidized lipids, diretinoids, and other components derived from the incomplete degradation of phagocytized photoreceptor outer segments (4).

A visual acuity test, ophthalmoscopic examination, FA, and OCT are very important for the early detection of Stargardt disease, but molecular testing is necessary for a reliable diagnosis (7).

Case Report

A 10-year-old female patient (born September 7, 1999) was followed-up for 4 years by an ophthalmologist because of a progressive reduction in visual acuity: OD=0.3 and OS=0.3 in 2006, OD=0.2 and OS=0.2 in 2007, and OD=0.08 and OS=0.1 in 2010. An ophthalmoscopic examination showed

Correspondence to D. Serapinas, Department of Pulmonology and Immunology, Medical Academy, Lithuanian University of Health Sciences, Eivenių 2, 50161 Kaunas, Lithuania
E-mail: dserapinas@gmail.com

yellow flecks in the maculae of both eyes (Fig. 1). On October 13, 2006, OCT was performed, and the patient was found to have a thin ($70\text{ }\mu\text{m}$ thinner than normal) atrophic neurosensory retina in the area of the fovea in both eyes, altered reflectivity in the layer of the photoreceptors in both eyes, and a thinner RPE in the subfoveal area in both eyes (Figs. 2 and 3). Stargardt disease was suspected. An ERG showed a loss of the scotopic b-waves; the scotopic a-wave was attenuated 2.5 times, the oscillatory potentials were missing, and there was a loss of the photopic a- and b-waves (Fig. 4). Based on the ERG findings, the abnormalities were typical of Stargardt disease type 3. In 2010, the patient was consulted by a neurologist. Incomplete convergence, an incomplete lateral movement in both eyes, slightly increased patellar tendon reflexes bilaterally, and a mild Babinski sign on the right was documented. With the aim to detect a presumable neurodegenerative disease, a magnetic resonance imaging (MRI) scan of the head was performed. The MRI revealed a small liquid collection in the subarachnoid space and the perineural area near to both eyes, but any neurodegenerative disease was neglected.

Family History

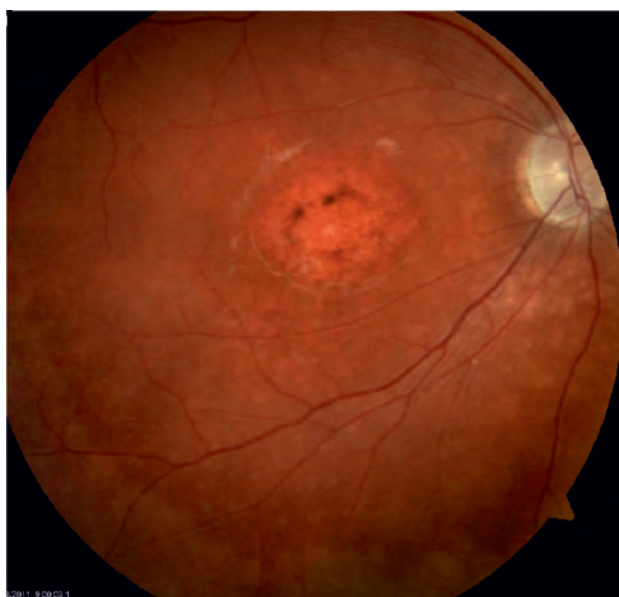Fig. 5 shows the scheme of possible inheritance of Stargardt disease. Both parents of the patient and her brother, aged 14 years, were healthy and had no clinical signs characteristic of Stargardt disease. No clinical signs typical of Stargardt disease were noted in the patient's grandparents, siblings of her both parents, and their children.

Genetic Testing

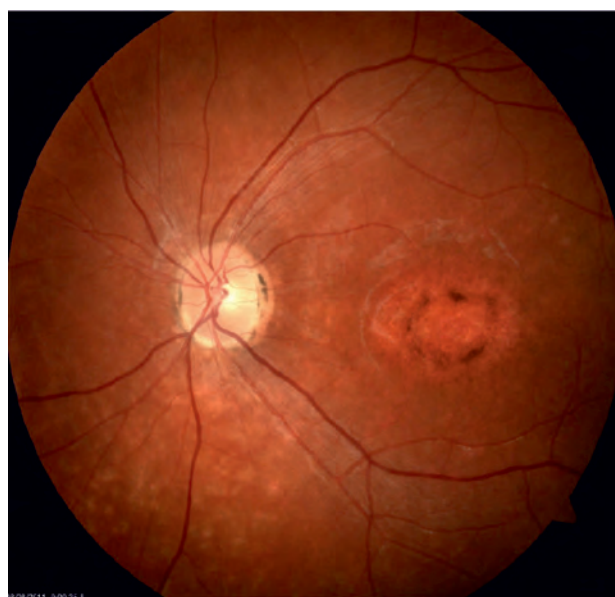For genetic testing, an EDTA blood sample (12 mL) of the patient was sent to the Institute of Human Genetics, University of Regensburg, Germany. The patient's sample was analyzed with the RetChip v.1.0 (STGD-module) array platform, which is based on a custom-designed Affymetrix GeneChip® microarray. This chip contains the following genes: *ABCA₄*, *CNGB₃*, and *ELOVL₄*. The analytic sensitivity for the detection of single nucleotide exchanges is about 90%; however, compared with Sanger sequencing, the detection rate for small insertions and deletions is lower. The pathogenic or unclear results from RetChip were confirmed by Sanger sequencing. The analysis of the DNA testing results showed 2 mutations in the *ABCA₄* gene: a nucleotide substitution in exon 12 (c.1622T>C; L541P) and a nucleotide substitution in exon 21 (c.3113C>T; A1038V). Both mutations were homozygous, which is rare in Stargardt disease.

Discussion

ABCA₄ is particularly challenging for molecular diagnosticians because this gene is extremely polymorphic with hundreds of allelic variants (8) that conditions the disease of different severity ranging from benign to nonfunctional (9). The allelic heterogeneity of *ABCA₄* affects the course of retinal diseases with varying severity and age of onset (8, 9). For our patient, a visual loss manifested at the age of 6 years, and in the period of 4 years, it progressed quite rapidly (visual acuity: OD=0.3 and OS=0.3 in 2006, OD=0.2 and OS=0.2 in 2007, and OD=0.08



A



B

Fig. 1. Fundus photographs of the right (A) and left (B) eyes. Accumulation of flecks can be seen in the maculae of both eyes.

STRATUS OCT
Normalize Process Report - 4.0.7 (0132)

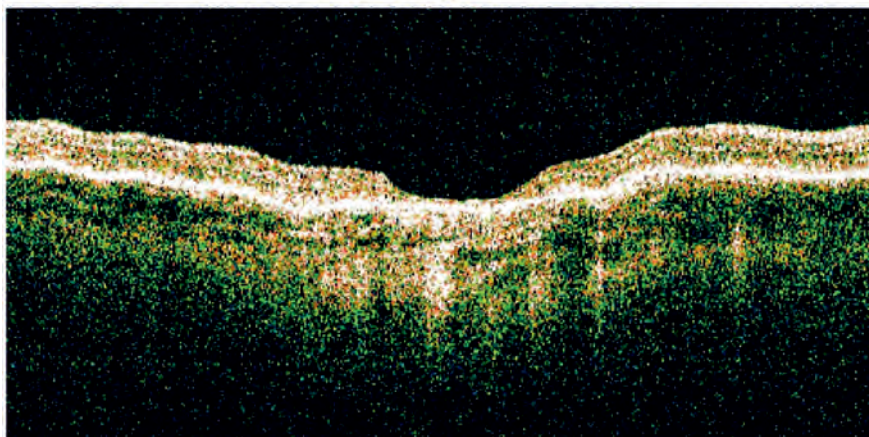

DOB: 9/7/1999, ID: NA, Female

Scan Type: Radial Lines OD

Scan Date: 10/14/2010

Scan Length: 6.0 mm

OCT Image



Signal Strength (Max 10)	9

Fundus Image



Scanned Image

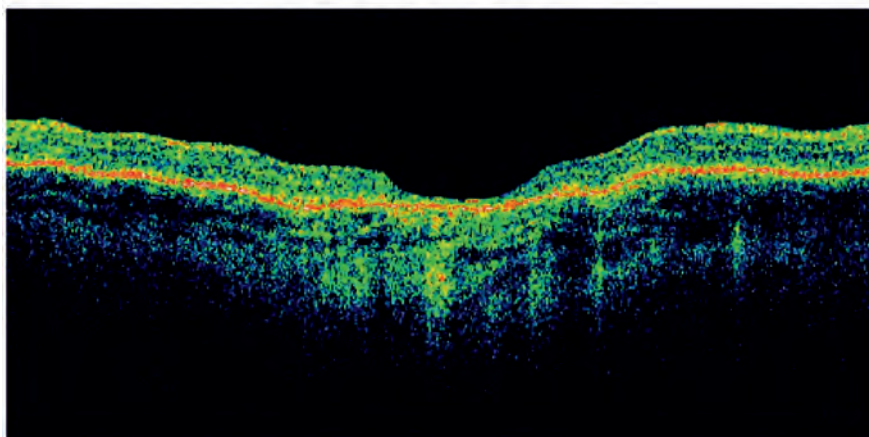


Fig. 2. Optical coherence tomography of the right eye

and OS=0.1 in 2010). According to the genotype-phenotype model, our findings indicate that mutations do interact to alter a clinical manifestation: a combination of 2 homozygous mutations could have an impact on the early age of the onset and severity of the disease. A genotype-phenotype model has also been proposed before, linking *ABCA₄* mutations, purported *ABCA₄* functional protein activity, and severity of the disease, as measured by the degree of visual loss and the age of the onset (10).

The present rare case of Stargardt disease was caused by 2 homozygous alleles that are called complex alleles, and based on Mendelian inheritance, it was expected that the father and the mother of the patient each carried the complex allele on one of their chromosomes and were not affected by Stargardt disease. A possible rare mechanism could also be paternal or maternal uniparental disomy of chromosome 1. To confirm this, a genetic analysis of the parents would be required; however, they refused to be tested.

STRATUS OCT
 Normalize Process Report - 4.0.7 (0132)

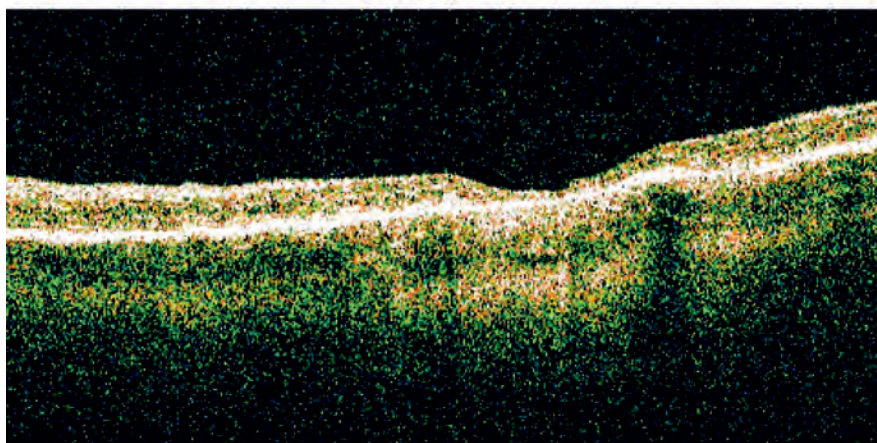

DOB: 9/7/1999, ID: NA, Female

Scan Type: Radial Lines OS

Scan Date: 10/14/2010

Scan Length: 6.0 mm

OCT Image



Signal Strength (Max 10)	8
--------------------------	---

Fundus Image



Scanned Image

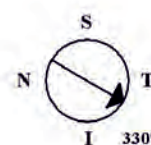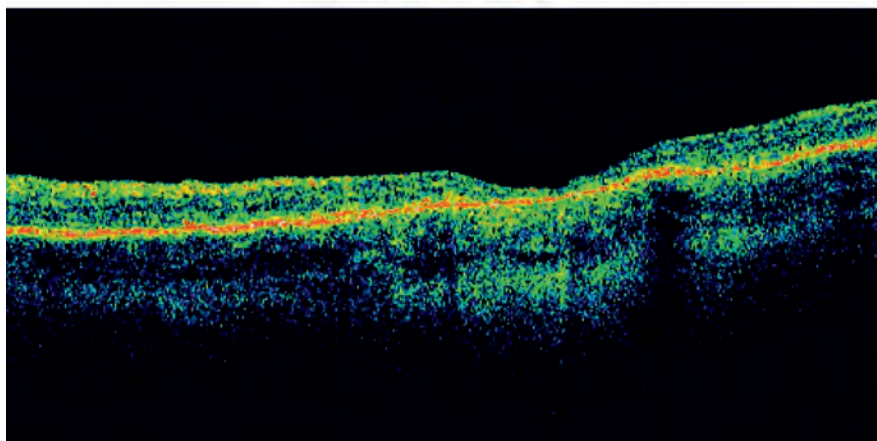



Fig. 3. Optical coherence tomography of the left eye

More than 500 mutations have been identified in *ABCA4*, including single-base substitutions, duplications, and deletions (11).

Several studies have identified frequent ethnic group-specific *ABCA4* alleles, such as the c.2588G>C variant resulting in a dual effect, p.G863A/delG863 as a founder mutation in Northern European patients with Stargardt disease, and a complex allele p.L541P/A1038V in the patients of the German origin who have both Stargardt disease

and cone-rod dystrophy. Complex *ABCA4* alleles are not a rare case in Stargardt disease. In fact, they are detected in approximately 10% of all patients with Stargardt disease (12).

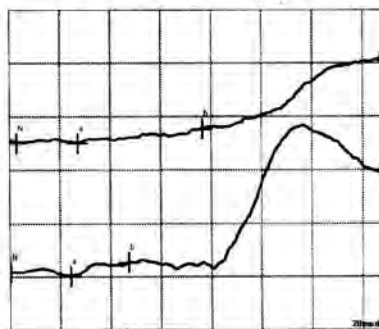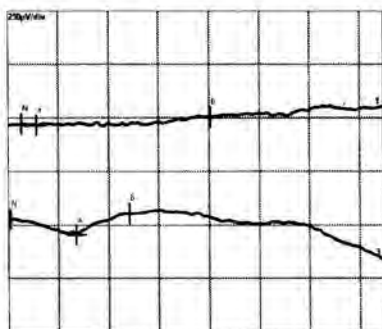
A mutational spectrum of *ABCA4* in Lithuania has not been assessed yet because of low frequency of Stargardt disease. Our presented mutations (L541P and A1038V) are not rare in Stargardt disease, but in this case, the disease was caused by a rare combination of double homozygous mutations.

RETiport32 	KMUK akių ligų klinika Eivenių 2, Kaunas		
	Patient: <u>A.B.</u> <u>9/7/1999</u> Tested: <u>10/14/2010 12:11:50 PM</u> ID:	Sex/Age: <u>F/11</u> Operator: <u>A.G.</u>	Electrode: <u>DTL Thread</u> Pupil Size: <u>nondil.</u>

Diagnosis:

V OU 0.3, R OU apie 2.0, pl.v. stiklai negerina. Iki siol akiniu nenesisojo.

vasl. ENG

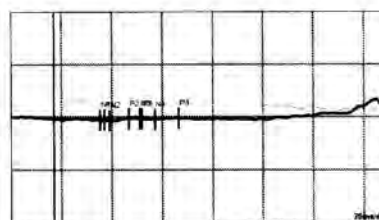
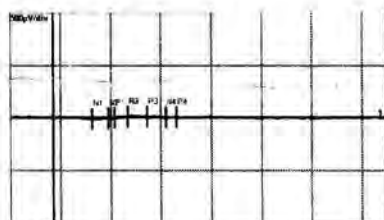


Channel	a [ms]	b [ms]	a-Welle	b-Welle
1 right -25dB	11	81	4.07μV	37.4μV
2 left -25dB	27	77	163nV	64.3μV
3 right 0dB	27	48	72.6μV	101μV
4 left 0dB	24	47	15.4μV	63.2μV

Group Values**1: Difference**



Cardinaly V.

N: 3ms, a: -16ms, b: 4ms, a-Welle: 3.91μV, b-Welle: -26.9μV



Channel	N1 [ms]	P1 [ms]	N2 [ms]	P2 [ms]	N3 [ms]	P3 [ms]	N4 [ms]	P4 [ms]	OS1	OS2	OS3	OS4
1 right 0dB 6	25	22	30	30	30	38	45	49	6.35μV	17.4μV	4.56μV	3.42μV
2 left 0dB 18	20	22	30	30	34	35	40	50	2.77μV	17.9μV	814nV	9.93μV

vasl. ENG



Channel	a [ms]	b [ms]	a-Welle	b-Welle
1 right 0dB	27	13	11.2μV	27.3μV
2 left 0dB	30	15	94.7μV	60.5μV

Group Values**1: Difference**

N: -2ms, a: -3ms, b: -2ms, a-Welle: -83.5μV, b-Welle: -33.2μV

Fig. 4. Electroretinogram of the patient

Based on the findings, such as the loss of the scotopic b-waves; attenuation of the scotopic a-wave by 2.5 times; missing oscillatory potentials; loss of the photopic a- and b-waves, this patient demonstrated the abnormalities typical of Stargardt disease type 3.

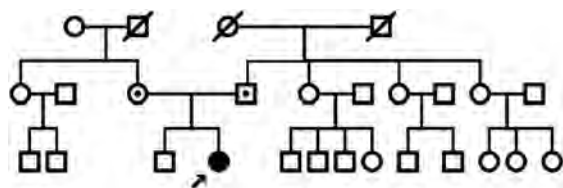


Fig. 5. Pedigree of the patient
The proband is marked with a filled circle.

A1038V, a missense mutation, is reported as one of the most common mutations in the *ABCA4* gene when is detected as a component of the complex allele L541P/A1038V. The complex allele demonstrates mislocalization and therefore reduced function of the ABCA4 protein, while the protein associated with A1038V alone does not mislocalize. A1038V is also pathogenic without L541P as it has a deleterious impact on ATPase by *ABCA4* in vitro (13).

When diagnosing an autosomal recessive disease, the sensitivity of the test is clinically important. First, the higher sensitivity of the test, the more probabilities to discover 2 alleles in affected individuals, to counsel them more accurately, and to administer mechanism-specific treatment that could be useful for them. Second, each increment of sensitivity of the test leads to an increase of the likelihood that observation of a single disease-causing variation in an individual is irrelevant to their disease. *ABCA4* genotypes cause many diverse phenotypes, and each of these phenotypes overlaps those caused by muta-

tions in other genes. This fact hampers the allelic diversity (8).

The 2 causative mutations detected in our case are also noteworthy with respect to personalized genomic medicine. An *ABCA4*-associated retinal disease is one of the most common causes of an inherited retinal disease in children and young adults, and a promising clinical trial of viral-mediated gene replacement in Stargardt disease is now being conducted (clinical trial identifier: NCT01367444) (8). However, such therapy emphasizes the need for sensitive and specific genetic testing for this disease because it is essential to be sure of the cause of a patient's disease for invasive mechanism-specific treatments like gene replacement. Thus, understanding the molecular mechanisms of a disease is important for researchers and clinicians.

Concluding Remarks

The phenotype of Stargardt disease is very variable. Age of onset, disease severity and progression, and instrumental examination data show phenotypic variability. Mutations in the *ABCA4* gene and their combinations may determine the phenotype of the disease.

The clinical case of Stargardt disease presented here is of interest because of the rare occurrence of 2 homozygous mutations, which may have resulted in a more severe phenotype.

Statement of Conflict of Interest

The authors state no conflict of interest.

References

1. Regillo C, Holekamp N, Johnson MW, Kaiser PK, Schubert HC, Hermann D. Retina and vitreous. San Francisco: American Academy of Ophthalmology; 2009. p. 225-54.
2. Allikmets R, Sing N, Sun H, Shroyer NF, Hutchinson A, Chidambaram A, et al. A photoreceptor cell-specific ATP-binding transporter gene (ABCR) is mutated in recessive Stargardt macular dystrophy. *Nat Genet* 1997;15:236-46.
3. Maugeri A, Klevering BJ, Rohrschneider K, Blankenagel A, Brunner HG, Deutman AF, et al. Mutation in the ABCA4 (ABCR) gene are the major cause of autosomal recessive cone-rod dystrophy. *Am J Hum Genet* 2000;67:960-6.
4. Molday RS, Zhang K. Defective lipid transport and biosynthesis in recessive and dominant Stargardt macular degeneration. *Prog Lipid Res* 2010;49:476-92.
5. Yannuzzi LA. The retinal atlas. Philadelphia: Saunders Elsevier; 2010. p. 7-182.
6. Truong SN, Dresner K, Telander DG, Morse LS, Small KW. Macular dystrophies. In: Yanoff M, Duker JS, editors. *Ophthalmology*. 3rd ed. Edinburgh: Mosby Elsevier; 2009. p. 560-9.
7. Friedman NJ, Kaiser PK, Trattler WB. Review of ophthalmology. Philadelphia: Elsevier Saunders; 2005. p. 89-158.
8. Braun TA, Mullins RF, Wagner AH, Andorf JL, Johnston RM, Bakall BB, et al. Non-exonic and synonymous variants in ABCA4 are an important cause of Stargardt disease. *Hum Mol Genet* 2013. [Epub ahead of print]
9. Duno M, Schwartz M, Larsen PL, Rosenberg T. Phenotypic and genetic spectrum of Danish patients with ABCA4-related retinopathy. *Ophthalmic Genet* 2012;33:225-31.
10. Heathfield L, Lacerda M, Nossek C, Roberts L, Ramesar RS. Stargardt disease: towards developing a model to predict phenotype. *Eur J Hum Genet* 2013;21:1173-6.
11. Aguirre-Lamban J, Riveiro-Alvarez R, Maia-Lopez S, Cantalapeira D, Vallespin E, Avila-Fernandez A, et al. Molecular analysis of the ABCA4 gene for reliable detection of allelic variations in Spanish patients: identification of 21 novel variants. *Br J Ophthalmol* 2009;93:614-21.
12. Zernant J, Schubert C, Im KM, Burke T, Brown CM, Fishman GA, et al. Analysis of the ABCA4 gene by next-generation sequencing. *Invest Ophthalmol Vis Sci* 2011;52:8479-87.
13. Burke TR, Tsang SH, Zernant J, Smith RT, Allikmets R. Familial discordance in Stargardt disease. *Mol Vis* 2012;18:227-33.

Received 9 June 2013, accepted 30 August 2013