

Multidisciplinary retroperitoneal and pelvic soft-tissue sarcoma case conferences: the added value that radiologists can provide

R.S. Lim MD,* A.Z. Kielar MD,*†‡§ R.H. El-Maraghi MD,§ M.A. Fraser MD MA,* C. Nessim MD,† and S. Thipphavong MD§

ABSTRACT

Clinical Vignette: A 50-year-old woman presents to the emergency department with increasing abdominal pain. Abdominal computed tomography imaging reveals an expanded inferior vena cava–filling defect that is suspicious for a retroperitoneal sarcoma, possibly a primary leiomyosarcoma of the inferior vena cava. The surgery team discusses the case with the radiologist, and all agree that there are multiple challenges with obtaining a tissue diagnosis and determining resectability. Thus, it is decided that this patient should be discussed at a multidisciplinary case conference.

In the present article, we feature a case-based scenario focusing on the role of the radiologist in this type of multidisciplinary team.

Key Words Multidisciplinary case conferences, tumour boards, cancer management, retroperitoneal soft-tissue sarcomas, value of radiology

Curr Oncol. 2017 June;24(3):e171-e175

www.current-oncology.com

INTRODUCTION

Multidisciplinary case conferences (mccs) are a growing area of physician collaboration designed to allow for evidence-based and patient-centred management in specialized cases. The goal is to improve patient outcomes in specific malignancies, including hepatobiliary cancer; colorectal and gastrointestinal cancer; breast cancer; melanoma; and genitourinary, gynecologic, and hematologic malignancies¹. Given the need for specialized care and close interaction with various physicians to treat those complex tumours, hospitals across North America are adopting this method of practice.

Multidisciplinary case conferences gather specialists from multiple health care teams including surgery, medical and radiation oncology, nursing, social work, nuclear medicine, pathology, and radiology. Currently, evidence shows that mccs lead to changes in patient diagnosis, improve patient management, and increase satisfaction for patients and physicians alike, although no prospective studies have demonstrated improvements in patient survival^{1,2}. The ultimate goal is to collaborate as trained specialists to maximize patient care and improve outcomes.

Cancer Care Ontario, an agency of the Ontario provincial government, is responsible for improving cancer services. In 2009, Cancer Care Ontario recommended that all patients diagnosed with sarcoma be reviewed at a mcc and that treatment be supervised by an experienced multidisciplinary sarcoma team in a specialized centre^{3,4}. Moreover, as part of Cancer Care Ontario's Provincial Sarcoma Services Plan, 3 centres in the province of Ontario have been designated sarcoma centres of excellence.

Clinical Vignette

A 50-year-old woman presents to the emergency department with increasing abdominal pain. Abdominal computed tomography (CT) imaging reveals an expanded inferior vena cava (IVC)–filling defect [Figure 1(A)] that is suspicious for a retroperitoneal sarcoma, possibly a primary leiomyosarcoma of the IVC. The surgery team discusses the case with the radiologist, and all agree that there are multiple challenges with obtaining a tissue diagnosis and determining resectability. Thus, it is decided that this patient should be discussed at a multidisciplinary case conference.

Correspondence to: Robert Lim, Department of Diagnostic Radiology, 501 Smyth Road, Box 232, Ottawa, Ontario K1H 8L6.
E-mail: rolim@toh.ca ■ DOI: <https://doi.org/10.3747/co.24.3478>

Retroperitoneal soft-tissue sarcomas, as presented in the foregoing clinical vignette, are rare tumours that account for fewer than 1% of all adult cancers. They often require complex management, thus calling for specialist care.

Although the role of radiologists in this specialized multidisciplinary setting is not always well known by all physicians, it is clear to those involved in sarcoma MCCs that radiologists play an essential role in supporting the medical and surgical decision-making process. Because the subtype and anatomic location of musculoskeletal soft-tissue sarcomas—and also retroperitoneal and pelvic sarcomas—affect both the surgical approach and the potential need for neoadjuvant therapy, the differential diagnosis made by the radiologist is an essential part of management. In the present article, we discuss the various roles of the radiologist, and the added value that the radiologist brings to specialized sarcoma MCCs and to patient care.

THE RADIOLOGIST'S ROLES

Diagnosis

An important role of radiology is to provide a succinct diagnosis or differential diagnosis. In the clinical vignette, location is key for the accurate diagnosis of a leiomyosarcoma. The initial imaging modality used is often CT, and identifying the tumour as “intravascular” and “within the IVC” is highly specific for the diagnosis, with a limited differential⁵. In other cases, a retroperitoneal mass can be extremely large, with obliteration of fat planes, making the exact site of organ origin difficult to determine. In such situations, magnetic resonance imaging can be useful in delineating tissue planes and determining the organ of origin, allowing for a more accurate diagnosis. Magnetic resonance imaging can also be helpful in preoperative planning for tumours that abut bone or involve vascular structures or nerves⁶.

Tissue Biopsy

In the clinical vignette, the patient's case was discussed at the sarcoma MCC, and a tissue diagnosis was required. A preoperative tissue diagnosis is often essential to determine treatment. Some lesions might be benign, requiring simple observation; others might require neoadjuvant therapy. Still others could turn out to be another malignancy, such as lymphoma, which requires very different management and has a different prognosis.

Image-guided biopsies should be performed only after consultation with the surgical oncologist for appropriate biopsy planning, because some lesions, based on radiologic findings, might not require biopsy at all; patients can proceed directly to surgery. For example, in some institutions, a retroperitoneal liposarcoma might not require presurgical tissue diagnosis. A high-grade heterogeneous dedifferentiated retroperitoneal liposarcoma can be confidently diagnosed on cross-sectional imaging and, after discussion at the MCC, can be resected en bloc when neoadjuvant therapy is not indicated⁴, avoiding tissue biopsy and eliminating the risk of seeding the biopsy track. In cases of low-grade well-differentiated liposarcoma as seen on imaging, pretreatment tissue diagnosis is sometimes avoided because of the theoretical risk of targeting the benign or low-grade tumour component, resulting in a false-negative biopsy.

When the diagnosis is not pathognomonic on imaging, or when preoperative neoadjuvant therapy is planned, core-needle biopsy is recommended. In other centres, all masses deemed to possibly represent sarcomas are biopsied, and molecular testing is performed (fluorescence *in situ* hybridization). In lipomatous tumours, fluorescence *in situ* hybridization utilizing *MDM2* and *CDK4* amplification will differentiate between benign lipomas and malignant liposarcomas⁷.

Careful biopsy planning by radiologists and surgical oncologists together will allow for high diagnostic yield. Radiologists carefully review preoperative imaging and selectively target the most aggressive-appearing portion of the lesion (for example, the soft-tissue component, avoiding areas of cystic necrosis or degeneration) that will give the most accurate representation of the tumour type and grade. Wu *et al.*⁸ evaluated the yield for diagnosing sarcomas in the extremities and confirmed that multiple cores of the high-grade portion provide the highest diagnostic yield. Those findings can be extrapolated to abdominal and pelvic soft-tissue sarcomas. Furthermore, core biopsies are essential for diagnostic yield because pathologists require tumour architecture to establish a diagnosis. Fine-needle aspiration samples are not useful and are not recommended for that reason. Risk of needle-track seeding is minimal and should not be a reason to avoid a biopsy when necessary to yield a diagnosis^{4,6}.

The surgeon's input into the biopsy plan is critical, and clear communication with the radiologist is key because treatment of the biopsy tract is required. At our institution, the radiologists and surgeons have developed a standardized sarcoma biopsy planner (Table 1). The biopsy planner includes patient and imaging information: patient details, referring physician, reference imaging, lesion size and location. It also includes the biopsy plan: patient positioning, imaging modality to be used, and the planned needle approach.

In our clinical vignette, the patient with the IVC mass was discussed at the MCC and, because of disease extent, preoperative neoadjuvant therapy was indicated, and a tissue diagnosis was required. The surgeons and radiologists discussed possible approaches for biopsy. Two approaches were considered: CT-guided retroperitoneal or transluminal performed by interventional radiology. Both options were feasible, but a CT-guided percutaneous right paravertebral approach, with the patient in the prone position, was chosen based on the subsequent posterior or retroperitoneal surgical approach and planned radiotherapy for treatment of the biopsy tract. The coaxial biopsy system is the standard CT-guided biopsy technique for consistent selection of the peripheral exophytic component [Figure 1(B)] to improve diagnostic yield and limit injury to the IVC vessel wall. Radiology often uses a coaxial biopsy technique to significantly lower the risk for seeding^{9,10}. The biopsy plan and approach were documented using the sarcoma planner, and at the MCC, the pathologist confirmed the diagnosis of an IVC leiomyosarcoma.

Preoperative Planning

Complete resection is the cornerstone of cancer management and offers the best chance of cure⁴. Radiologists play an essential role at MCCs to help determine the likelihood

TABLE 1 Sample sarcoma biopsy planner

Patient information	
Patient name, medical record number	<i>Specify</i>
Referring physician	<i>Specify</i>
Imaging findings	
Studies	<i>Date, type (CT, MR, PET-CT)</i>
Series plane, series number, image number	<i>Notes: Axial plane is preferred for planning CT-guided biopsy. Specify the type (T2, T1Gd, non-contrast CT, contrast-enhanced CT, etc.), series number, and image number so that the radiologist can quickly identify where tissue has to be taken.</i>
Lesion location and size	<i>Right, left, or midline; retroperitoneal space; general location; and maximum diameter Consider creating a montage on the picture archiving and communication system for the biopsy radiologist to review. Select the highest-grade (solid) target.</i>
Biopsy plan	
Patient positioning	<i>Prone, supine, right or left decubitus, lithotomy, other</i>
Modality	<i>CT, ultrasonography, other</i>
Route	<i>Posterior, anterior, transgluteal, lateral, pelvic, transvaginal, transrectal, transpleural, other</i>
Needle gauge	<i>Select the largest coaxial system feasible, and take many passes to optimize diagnostic yield, especially for masses that are more lower-grade in appearance</i>
Conscious sedation	<i>Yes or no</i>
Special considerations	
Anticoagulants? Recent bloodwork?	<i>This information is part of the booking process, but if the protocoling radiologist has specific knowledge or recommendations, then it is helpful to document it or them here. If the international normalized ratio and platelets are known, document them here.</i>
Comorbidities?	<i>Comorbidities? Biliary or ureteric obstruction? Is competence to give consent an issue? Caregiver to contact?</i>
Other comments?	

CT = computed tomography; MR = magnetic resonance; PET = positron-emission tomography; Gd = gadolinium.

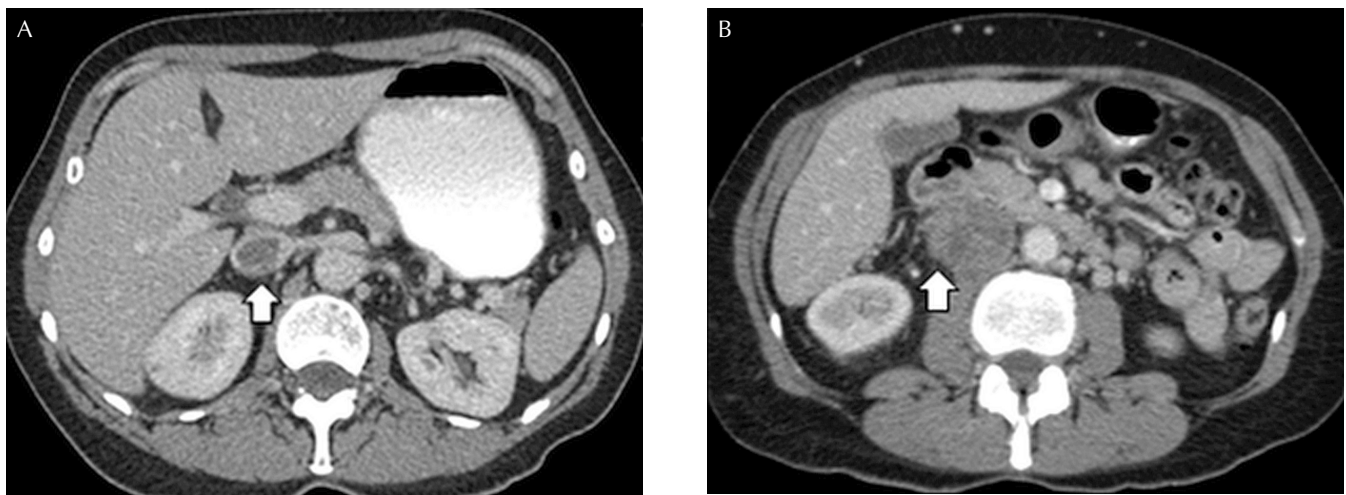


FIGURE 1 In a 50-year-old woman with an inferior vena cava (IVC) leiomyosarcoma, axial contrast-enhanced computed tomography demonstrates (A) an IVC-filling defect (arrow) with (B) local exophytic infiltration (arrow).

of resectability. Specifically, radiologists help to determine if vital organs are invaded by tumour and cannot be resected. To ensure negative margins, en bloc resection with adjacent structures or organs (and thus multi-visceral resections) are often required⁹. Imaging helps to define involved margins and structure boundaries to help decide which adjacent tissues might need to be resected together with the tumour.

In tumours that are borderline resectable, or that are resectable but of high grade, neoadjuvant radiation or chemotherapy might be recommended before surgery. For leiomyosarcomas of the IVC, surgical resectability depends on the location: 50.8% arise from the middle IVC, 44.2% from the lower IVC, and 4.2% from the upper IVC (the latter being least amenable to surgical resection)⁵. Resection of the tumour with the IVC en bloc, with venous reconstruction, is often required. If the tumour is borderline resectable, the goal of preoperative radiation or chemotherapy (or both) is to shrink the tumour to allow for surgical resection⁴.

Assessing Response to Neoadjuvant Treatment

Radiologists are involved in patient management when assessing the imaging response to neoadjuvant therapy. Re-staging scans are performed with the goal of reassessing tumour size and margins with adjacent organs. Assessment for distant metastatic disease is also required before surgery. Surgeons rely on cross-sectional imaging to show response to treatment and to evaluate the extent of resection that will allow for complete en bloc resection and potential cure, especially in the case of a tumour previously deemed borderline resectable.

Evaluation of Postoperative Complications

Radiologists play an important role in the detection of acute and long-term complications. Acute postoperative complications vary depending on the site of the sarcoma and the resection that was performed. The organs most commonly resected en bloc with a retroperitoneal sarcoma are, in order of frequency, the kidney, colon, spleen, pancreas, small bowel, and diaphragm¹¹. Thus, complications range from bleeding, pneumothorax, pancreatic leak, and gastrointestinal anastomotic leak, to abscess formation—all of which can be readily detected by imaging. Long-term complications can include adhesions, bowel strictures, small-bowel obstructions, and abdominal wall incisional hernias. Computed tomography imaging is the modality most commonly used for the assessment of complications, although magnetic resonance imaging can be helpful as well, particularly for evaluation of pelvic organs.

Posttreatment Surveillance

Risk of recurrence unfortunately does not plateau after complete resection of a soft-tissue sarcoma; recurrences can happen 15–20 years later. The Retroperitoneal Sarcoma Consensus statement therefore recommends indefinite follow-up for this patient population⁴. Regular follow-up surveillance includes CT imaging of chest, abdomen, and pelvis every 3–6 months for 2–5 years and then annually.

Evidence of local recurrence without distant metastatic disease can be an indication for re-excision⁶. Such cases are often re-presented at MCCs for discussion of

management. In those cases, radiology plays an essential role in determining if an image is more likely to represent local recurrence or simply postoperative fibrosis. Image-guided biopsy is useful and often necessary to confirm recurrence in those situations and helps to guide treatment strategies, given that re-excision is often challenging. If resection is being considered, neoadjuvant radiation or chemotherapy (or both) might be considered, depending on the modalities previously used for the primary sarcoma.

If, at cross-sectional imaging, the recurrence is found to be unresectable because of invasion of vital structures or concomitant distant metastases, radiation therapy might still be an option, depending on the patient's symptoms and on whether radiation treatment was administered to the original tumour. For disseminated metastatic disease, supportive care might be considered⁹. Palliative surgery is often unsuccessful and is not recommended^{4,6}.

For the patient in the clinical vignette, a primary surgical resection was successfully performed. No immediate postoperative complications occurred, and initial follow-up surveillance did not reveal recurrent disease. The patient then underwent postoperative adjuvant radiation therapy. Follow-up is currently being conducted by the surgical oncologist, and the patient is doing well, with regular active surveillance and no evidence of recurrent disease.

SUMMARY

As illustrated by the clinical vignette, radiologists are integral members of the MCC team and—from initial diagnosis and surgical planning to follow-up surveillance—provide added value in the management of patients diagnosed with abdominal and pelvic sarcomas. Clear and standardized communication between radiologists and multiple health care professionals is essential in the setting of a MCC and optimizes patient care. Creation of care maps is important to ensure that these rare sarcomas are treated in a facility that is equipped and organized to provide excellent multidisciplinary care to improve patient outcomes.

CONFLICT OF INTEREST DISCLOSURES

We have read and understood *Current Oncology's* policy on disclosing conflicts of interest, and we declare that we have none.

AUTHOR AFFILIATIONS

*The Ottawa Hospital and University of Ottawa, Ottawa; †The Ottawa Hospital Research Institute, Ottawa; ‡Royal Victoria Regional Health Centre, Barrie; and §University Health Network and University of Toronto, Toronto, ON.

REFERENCES

1. Croke JM, El-Sayed S. Multidisciplinary management of cancer patients: chasing a shadow or real value? An overview of the literature. *Curr Oncol* 2012;19:e232–8.
2. Brar SS, Hong NL, Wright FC. Multidisciplinary cancer care: does it improve outcomes? *J Surg Oncol* 2014;110:494–9.
3. Cancer Care Ontario. *Adult Sarcoma Management in Ontario: Expert Panel Report 2009*. Toronto, ON; Cancer Care Ontario; 2009.
4. Trans-Atlantic RPS Working Group. Management of primary retroperitoneal sarcoma (RPS) in the adult: a consensus approach from the Trans-Atlantic RPS Working Group. *Ann Surg Oncol* 2015;22:256–63.

5. Kandpal H, Sharma R, Gamangatti S, Srivastava DN, Vashisht S. Imaging the inferior vena cava: a road less traveled. *Radiographics* 2008;28:669–89.
6. Trans-Atlantic RPS Working Group. Management of recurrent retroperitoneal sarcoma (RPS) in the adult: a consensus approach from the Trans-Atlantic RPS Working Group. *Ann Surg Oncol* 2016;23:3531–40.
7. Sirvent N, Coindre JM, Maire G, *et al.* Detection of *MDM2-CDK4* amplification by fluorescence *in situ* hybridization in 200 paraffin-embedded tumor samples: utility in diagnosing adipocytic lesions and comparison with immunohistochemistry and real-time PCR. *Am J Surg Pathol* 2007;31:1476–89.
8. Wu JS, Goldsmith JD, Horwich PJ, Shetty SK, Hochman MG. Bone and soft-tissue lesions: what factors affect diagnostic yield of image-guided core-needle biopsy? *Radiology* 2008;248:962–70.
9. Demetri GD, Antonia S, Benjamin RS, *et al.* Soft tissue sarcoma. *J Natl Compr Canc Netw* 2010;8:630–74.
10. Maturen KE, Nghiem HV, Marrero JA, *et al.* Lack of tumor seeding of hepatocellular carcinoma after percutaneous needle biopsy using coaxial cutting needle technique. *AJR Am J Roentgenol* 2006;187:1184–7.
11. Gronchi A, Casali PG, Fiore M, *et al.* Retroperitoneal soft tissue sarcomas: patterns of recurrence in 167 patients treated at a single institution. *Cancer* 2004;100:2448–55.