

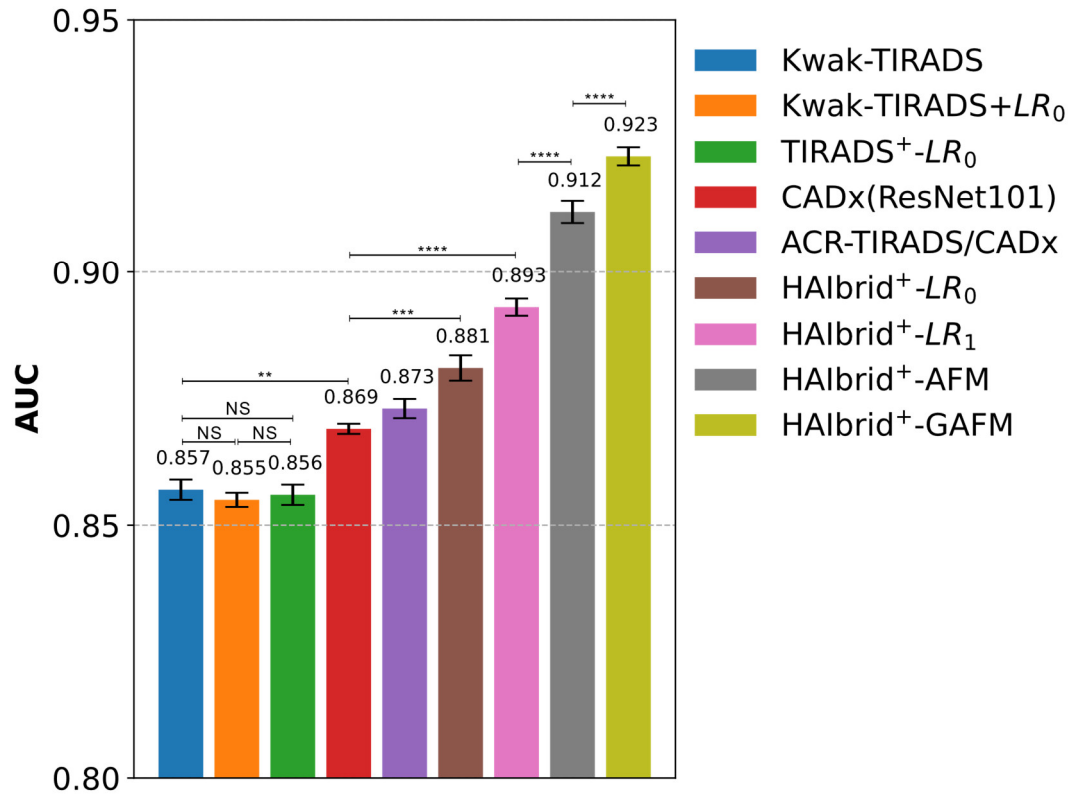Figure S1. Bar plot of the mean AUC values in diagnosing thyroid nodules from 10-fold cross-validation experiments on 3002 nodules and the statistical comparisons. The mean AUC values are provided at the top of each bar and the corresponding standard deviations are displayed as error bars. For the sake of clarity, only a few statistical comparisons with the associated significance levels (indicated by the number of stars) are provided and “NS” sign indicates non-significant difference between compared cases. The meanings of LR_0 , LR_1 and the + sign are referred to descriptions in Appendix Table 1.

Table S1. Our HAIbrid-TIRADS criteria returned by the proposed GAFM model for thyroid nodule malignancy risk stratification from the cross-validation cohort.

Feature		Score	Odds ratio
<i>Malignant as diagnosed by CADx</i>		8	10.923
<i>Shape</i>	Taller than wide	3	4.206
	Wider than tall	0	1.045
<i>Margin</i>	Extra-thyroidal extension	4	6.102
	Irregular	3	5.686
	Ill-defined	1	2.107
<i>Composition</i>	Solid	3	3.357
	Predominantly solid	1	2.312
<i>Echogenicity</i>	Marked hypoechoic	4	7.812
	Hypoechoic	1	2.713
	Isoechoic	0	1.054
	Anechoic	0	1.023
<i>Echogenic foci</i>	Micro-calcifications	4	6.834
	Punctate echogenic foci of undetermined significance	1	1.891
<i>vasculature</i>	Mainly perinodular and not twisted	2	2.349

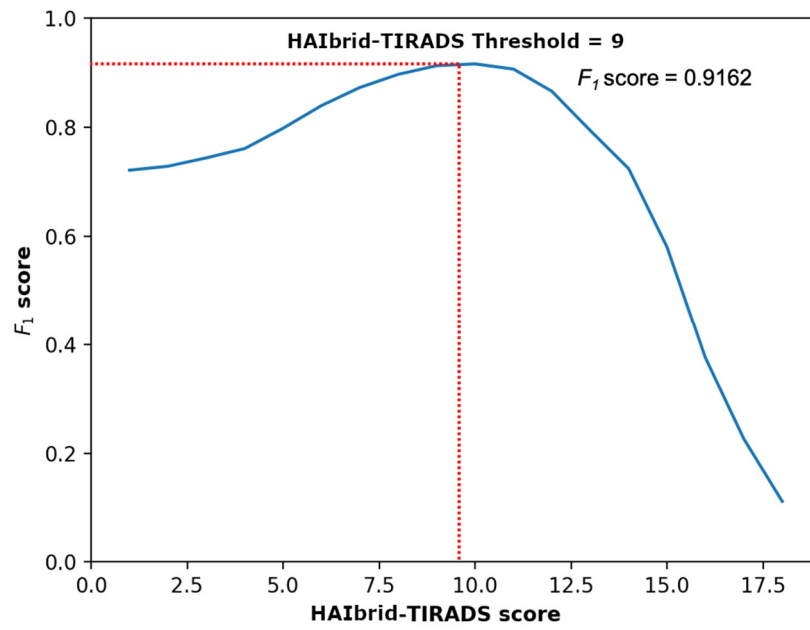


Figure S2. The identification of the optimal threshold to separate malignant from benign samples based on F_1 score computed using our HAIbrid-GAFM model.

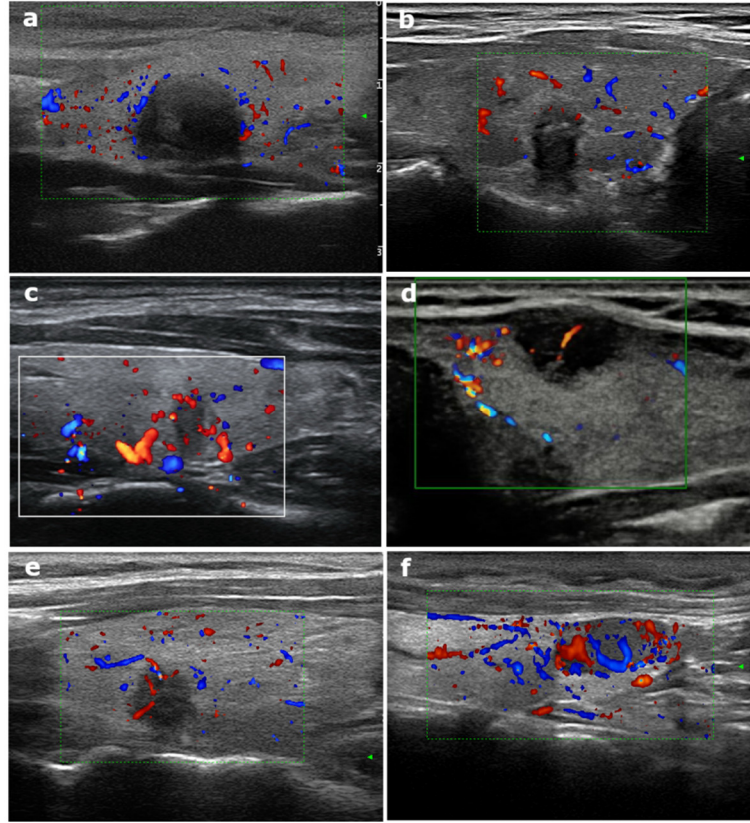


Figure S3. Representative images for additionally defined vasculature-related features. (a) Circumscribed solid nodule with avascularity diagnosed as nodular goiter (b) Irregular solid nodule with untwisted perinodular vascularity diagnosed as papillary thyroid carcinoma (c) Irregular solid nodule with twisted mainly perinodular vascularity diagnosed as papillary thyroid carcinoma (d) Irregular solid nodule with untwisted mainly intranodular vascularity, diagnosed as papillary thyroid carcinoma (e) Irregular solid nodule with untwisted mainly perinodular vascularity, diagnosed as papillary thyroid carcinoma (f) Circumscribed solid nodule with twisted mixed vascularity, diagnosed as nodular goiter.