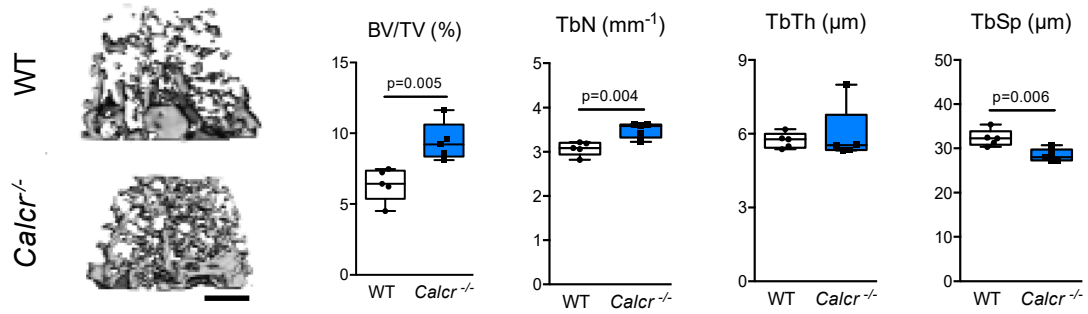


Supplementary materials:



Supplementary Figure S1. High bone mass in the distal femur of mice lacking CTR. Representative μ CT images of the trabecular bone in the distal shaft area of the femur derived from untreated WT and CTR-deficient (*Calcr*^{-/-}) mice at the age of 14 weeks (left; scale bar = 500 μ m.), and radiologic quantification of indicated bone parameters (right). n = 5 mice per group.