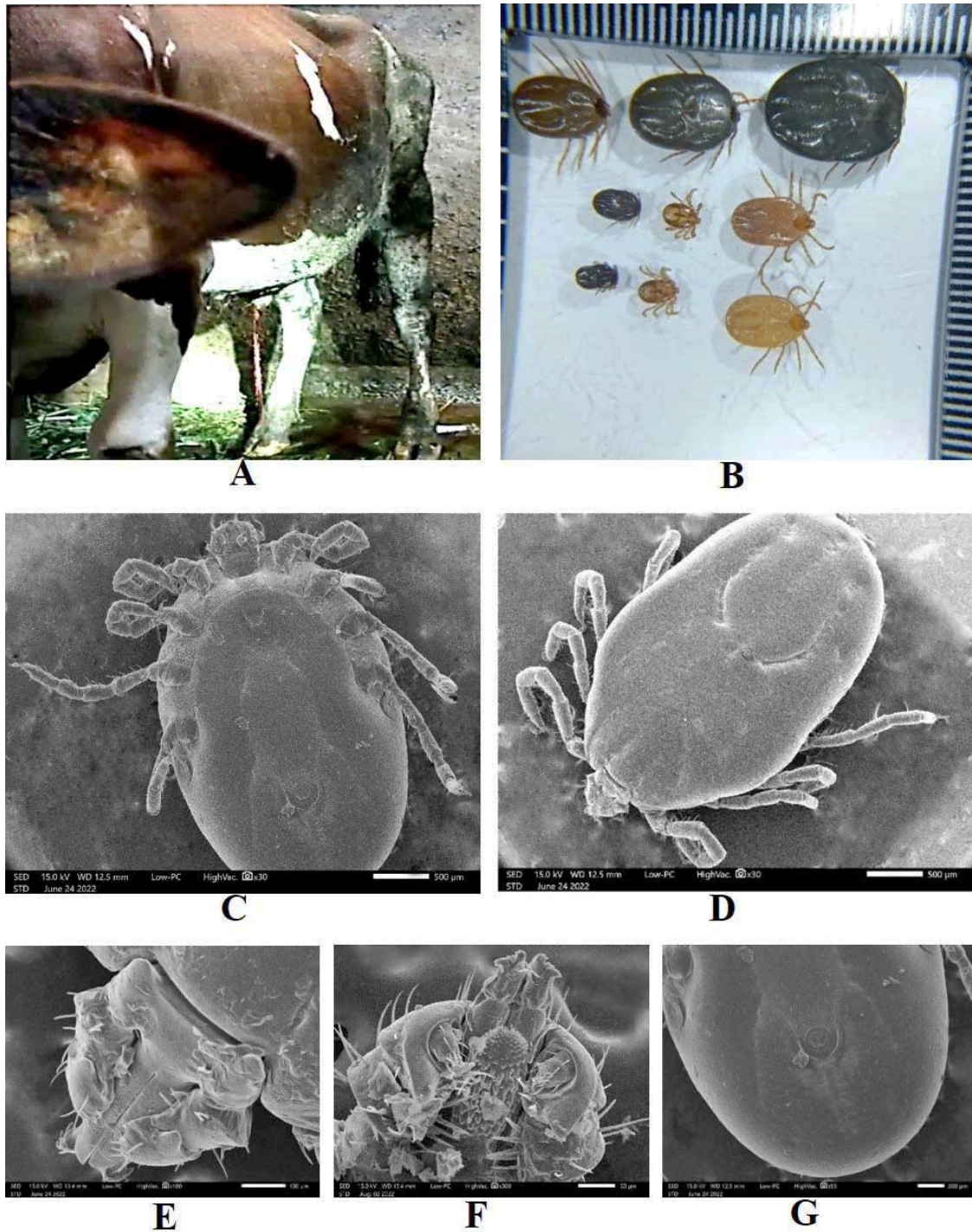


## Supplementary materials



**Figure 1.** Clinical signs associated with bovine babesiosis in Boyolali, Central Java, and ticks randomly found during blood collection. A Holstein-Friesian calf with hematuria (hemoglobinuria) (A). *H. bispinosa* in various stages (B). Scanning electron microscopy of a tick, dorsal view (C), ventral view (D), gnathostome (E) and hypostome (F), ventral posterior view (G)

