

Article

Non-Surgical Touch-Up with Hyaluronic Acid Fillers Following Facial Reconstructive Surgery

Fabrizio Chirico ^{1,*} , Giuseppe Colella ², Antonio Cortese ³ , Pierfrancesco Bove ⁴, Romolo Fragola ² , Luigi Rugge ⁵, Giovanni Audino ⁶ , Nicola Sgaramella ⁷ and Gianpaolo Tartaro ²

¹ Independent Researcher, 80136 Naples, Italy

² Maxillofacial Surgery Unit, Multidisciplinary Department of Medical-Surgical and Dental Specialities, University of Campania “Luigi Vanvitelli”, 80138 Naples, Italy; giuseppe.colella@unicampania.it (G.C.); romolofragola@gmail.com (R.F.); gianpaolo.tartaro@unicampania.it (G.T.)

³ Maxillofacial Surgery Unit, Department of Medicine and Surgery, University of Salerno, 84125 Salerno, Italy; ancortese@unisa.it

⁴ Independent Researcher, 20121 Milan, Italy; dr.pierfrancesco.bove@gmail.com

⁵ Independent Researcher, 73100 Lecce, Italy; luigirugge@gmail.com

⁶ Maxillofacial Surgery Unit, Department of Neurosciences, Reproductive and Odontostomatological Sciences, University Federico II, Via Pansini 5, 80100 Naples, Italy; audinodr.giovanni@gmail.com

⁷ Independent Researcher, 70125 Bari, Italy; sgaramellanicola12@gmail.com

* Correspondence: fabriziochirico@hotmail.com; Tel.: +39-3283678855

Abstract: The use of hyaluronic acid (HA) injectable fillers has become increasingly widespread in facial recontouring and rejuvenation. We report our experiences to emphasize the role of HA fillers as tools beyond aesthetic treatments in cases of post-surgical facial sequelae. HA fillers are generally used for aesthetic rejuvenation, but one potential new horizon could be their application in trauma, reconstructive, and craniofacial surgery. This study was conducted retrospectively, evaluating medical reports of patients treated at the Maxillofacial Surgery Unit, University of Campania “Luigi Vanvitelli”, Naples, for lip incompetence, trauma, oncological, reconstructive, and craniosynostosis surgery sequelae. Visual analog scale (VAS) evaluation was performed to assess patient satisfaction. No major complications (i.e., impending necrosis or visual loss) were reported. Bruising and swelling was reported for 48 h after lip injection. At the immediate VAS evaluation, 67% of the patients were “extremely satisfied” and 33% “satisfied”. In those 33%, VAS scores changed to “extremely satisfied” at 6–9 weeks and 3–6 months of VAS evaluation (contextually to improvement in tissue flexibility, elasticity, and aesthetic appearance). Results indicate that this minimally invasive approach achieves a high level of aesthetic enhancement, improving patient satisfaction. The concept of HA filler applications could be a frontier that may be applicable to other areas of reconstructive facial plastic surgery.

Keywords: facial reconstruction; craniosynostosis; facial trauma; post-surgical facial sequelae; hyaluronic acid filler; facial plastic surgery; craniomaxillofacial surgery; reconstructive surgery; surgical oncology; non-surgical approach



Citation: Chirico, F.; Colella, G.; Cortese, A.; Bove, P.; Fragola, R.; Rugge, L.; Audino, G.; Sgaramella, N.; Tartaro, G. Non-Surgical Touch-Up with Hyaluronic Acid Fillers Following Facial Reconstructive Surgery. *Appl. Sci.* **2021**, *11*, 7507. <https://doi.org/10.3390/app11167507>

Academic Editor: Yong-Deok Kim

Received: 22 July 2021

Accepted: 12 August 2021

Published: 16 August 2021

Publisher’s Note: MDPI stays neutral with regard to jurisdictional claims in published maps and institutional affiliations.



Copyright: © 2021 by the authors. Licensee MDPI, Basel, Switzerland. This article is an open access article distributed under the terms and conditions of the Creative Commons Attribution (CC BY) license (<https://creativecommons.org/licenses/by/4.0/>).

1. Introduction

The use of hyaluronic acid (HA) injectable fillers has become increasingly widespread in facial recontouring and rejuvenation, with significant relevance in plastic surgery. Even with increasing popularity of facial tissue augmentation in recent years, it is not a new theory. A fat grafting technique was introduced more than a century ago [1]. Other materials, such as polymethylmethacrylate (PMMA), hydroxyapatite cement (HAC), paraffin, and silicone have been utilized with overriding limitations (e.g., toxicity and foreign body reactions) [2]. It was only in the past two decades that safe, biocompatible, non-allergenic, and injectable hyaluronic acid (HA) filler products were developed and approved by the U.S. Food and Drug Administration [3]. According to the American Society of Plastic

Surgeons' 2020 statistics [4], the use of HA fillers in facial non-surgical contouring has significantly increased due to their versatility, effectiveness, and rare adverse reactions [5]. Moreover, the number of available HA injectable fillers for facial recontouring has raised dramatically in the last several years and the range of products to choose from has also been impressively expanded through innovative fillers manufacturing technologies. Different products could share the same indications, yet consist of very different physicochemical profiles [6,7]. These features distinguish products according to functionally important aspects and have become effective ways for surgeons to select which materials are the most suitable for a given surgical need.

Compared to surgery, they provide facial rejuvenation and aesthetic enhancement at a lower cost, with less complications, minimal downtime, and immediate results. Although HA injections are excellent tools utilized in facial cosmetic improvements, they could also be applied to treat facial deformities resulting from traumatic events, orbital and periorbital surgeries, tumor resections, congenital deformities, burns, scars, and facial palsy [8–11]. Injective techniques could also be utilized for HIV-related facial lipoatrophy or progressive hemifacial atrophy [12–17]. Although hyaluronic acid is widely used for cosmetic purposes, in the literature, little is known about this procedure in reconstructive approaches [8–19].

Facial reconstruction is considered one of the most challenging procedures in plastic surgery; despite the refinement of current techniques, disfiguring anomalies are frequently observed postoperatively, in the form of slightly hollow scars, insufficiently marked lips, asymmetries localized in the nose, skull, midface, chin, or mandibular angle [20–25]. Aesthetic improvement is demanded from these patients (who are usually teenagers or who have undergone many troublesome surgeries) [22–24]. Viscoelastic properties, hydrophilicity, affordability, safety, biocompatibility, effectiveness, and the non-immunogenicity of HA fillers have prompted us to use this approach in these indications. Determining the appropriate HA gel is based on multiple variables, including ease of injection, longevity, surgeon preference, and cost-effectiveness. Key variables that characterize the behavior of a hyaluronic acid-based filler (to determine the most appropriate gel for every reconstructive purpose) include cohesivity, crosslinking, and HA concentration.

We report our experiences with to emphasize the role of HA fillers as tools beyond aesthetic treatments in facial plastic reconstructive surgery and aesthetic medicine. HA fillers are generally used for aesthetic rejuvenation, but one potential new horizon could be their application in trauma, reconstructive, and craniofacial surgery.

2. Materials and Methods

This study was conducted retrospectively, evaluating medical reports of patients treated at the Maxillofacial Surgery Unit of the University of Campania “Luigi Vanvitelli”, Naples. The study was approved by the internal ethics committee at the University (AOU Università della Campania Vanvitelli—0019140/i). A total of 6 patients (4 men and 2 women; age range, 26–75), from May 2019 to May 2021, were collected.

Eligible criteria for inclusion: aged 18 and older, previous craniomaxillofacial oncological surgery, craniosynostosis surgery sequelae, history of facial trauma, reconstructive facial surgery sequelae. Excluded from participation were patients already receiving facial injections of any other product. Other exclusion criteria were any active infections on the face, chemotherapy, radiotherapy, pregnancy, breastfeeding, and poorly controlled diabetes mellitus. A visual analog scale (VAS) evaluation was performed to assess patient satisfaction immediately, 6–9 weeks, and 3–6 months after procedure, where 0 represented “Not satisfied” and 100 “Extremely satisfied”.

2.1. Case 1

A 26-year-old man with a history of facial trauma was referred to the Maxillofacial Unit at University of Campania “Luigi Vanvitelli”, Naples. After the traumatic event, the patient experienced only swallowing without functional impairment. His family doctor suggested pharmacological therapy to reduce edema. Swallowing disappeared a few weeks later,

and the patient noted facial asymmetry; thus, he underwent a computed tomography (CT) evaluation. TC results showed a complete fracture of the zygomatic arch.. After several surgical counseling sessions, the patient arrived at our department 9 months after trauma. Clinical assessment was performed, with the aim to exclude functional disorders, such as reduction in mouth opening. A diagnosis of a poor consolidated malar bone fracture was confirmed at the CT scan examination (Figure 1).

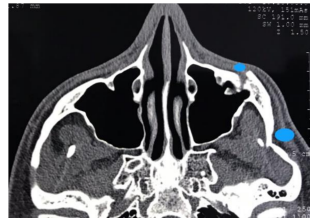

Figure 1. CT imaging of the left displaced malar fracture. Blue dots describe HA injection deep to the bone.

We proposed both surgical and non-surgical approaches. In the surgical option, reduction and rigid fixation was suggested. The non-surgical option was based on HA filler injection to restore the proper projection of the injured side. The patient, clearly informed about the non-permanent effect of the procedure, opted for the non-surgical approach. After careful radiological evaluation, we injected 1 mL of VYC-20L, a 20-mg/mL, 1,4-butanediol diglycidyl ether (BDDE) cross-linked, HA gel (Juvèderm Voluma with Lidocaine, Allergan Inc., Irvine, CA, USA) deep to the bone, 0.2 mL in medial area, 0.4 mL in two points in the lateral area. We then injected 1 mL of VYC-17L, a 17.5 mg/mL, 1,4-butanediol diglycidyl ether (BDDE) cross-linked, HA filler (Juvèderm Volift with Lidocaine, Allergan Inc., Irvine, CA, USA) in the subcutaneous layer with cannula, with the aim to restore malar projection (Figure 2).



Figure 2. Preoperative marking of a patient presenting poor consolidated malar bone fracture.

The patient was followed up for 1-year showing stable results (Figures 3 and 4).

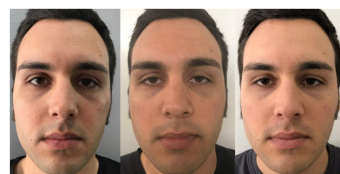

Figure 3. Preoperative, 2- and 12-months postoperative frontal view results of the same patient shown in Figure 2.



Figure 4. Preoperative, 2- and 12-months postoperative, three-quarter left view results of the same patient shown in Figure 2.

2.2. Case 2

A 54-year-old female patient referred to our department for labial incompetence management (Figure 5).

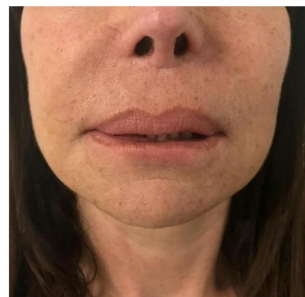

Figure 5. Frontal view of 54-year-old Caucasian woman presenting lip incompetence.

Lip incompetence and lower teeth display at rest were secondary to an excessive resection of lower lip mucosa after lip implant removal performed by another surgeon. The patient was scheduled to have surgical repair of the defect, with the aim to achieve lip restoration. During preoperative evaluation, a solitary pulmonary nodule revealed lung cancer. For this reason, a cosmetic surgical approach could not be performed. Thus, a minimally invasive procedure was offered to temporarily improve her lip appearance. Hyaluronic acid injections were planned. Injections were performed with a 15 mg/mL, 1,4-butanediol diglycidyl ether (BDDE) cross-linked, HA filler (Teosyal PureSense Redensity II, Teoxane, Geneva, Switzerland). A total of 3 mL of HA filler was injected. HA perpendicular injections were performed through the skin, into the inner side of the lip, to obtain lip eversion, and to recruit tissues to cover the lower displayed teeth. No touch-up was required. At 3- and 6 month follow-ups, stable results were observed (Figures 6 and 7).

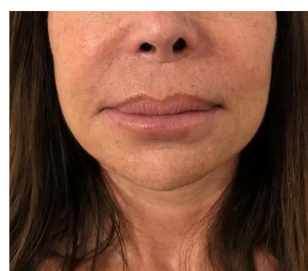

Figure 6. Frontal view of the same patient shown in Figure 5 at the 3-month follow-up of hyaluronic acid injections performed to restore lip competence.

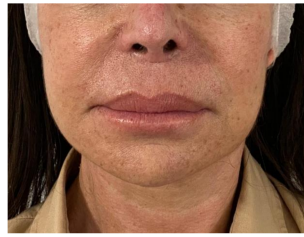

Figure 7. Frontal view of the same patient shown in Figure 5 at the 6-month follow-up of hyaluronic acid injections performed to restore lip competence.

2.3. Case 3

A 34-year-old man was referred to the Department of Craniomaxillofacial Surgery of the University of Campania “Luigi Vanvitelli”, Naples. The patient was treated for sagittal craniosynostosis at 6 months old and the reconstructive procedure was performed via a bicoronal approach. In spite of the effectiveness of the surgical procedure, the stigmata were not totally hidden. A bilateral hollow was present in the temporoparietal area (Figure 8).

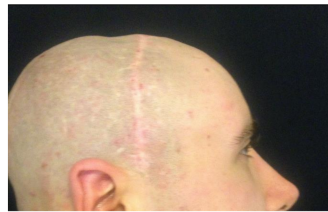

Figure 8. A 34-year-old man with craniosynostosis surgery sequelae.

The patient asked for non-surgical cosmetic enhancement of the region; thus, he underwent the HA filler injection approach. Five multiple injective sessions of 28 mg/mL, polyethylene glycol diglycidyl ether (PEGDE) cross-linked, HA hydrogel (Neauvia Organic Intense, Matex Lab, Lugano, CH) were required to achieve the excellence of morphological results.

According to the preoperative planning, the senior author injected deep to the bone, in order to improve volumetric deficiencies and to restore the eurhythmy of the temporoparietal shape. A total of 4 mL of HA filler was injected to each side during each injective session (Figure 9).

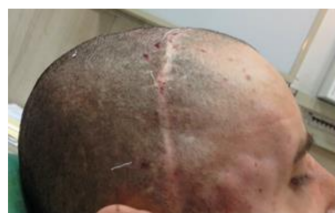

Figure 9. Immediate postoperative lateral right view result of the same patient shown in Figure 8.

At the 13-month follow-up, we assessed the stability of the results (Figure 10).

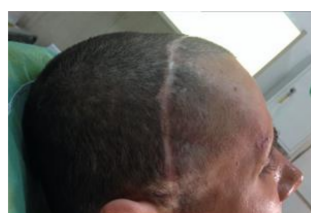


Figure 10. The 13-month postoperative lateral right view result of the same patient shown in Figure 8.

2.4. Case 4

A 59-year-old female patient with prior smoking history presented to our Craniomaxillofacial Surgery Unit for evaluation of a mass near the angle of her left mandible. Fine needle aspiration (FNA) cytology was consistent with pleomorphic adenoma, and preoperative magnetic resonance imaging (MRI) showed a 63–47–35 mm solid mass involving superficial and deep lobes of the parotid gland. The patient underwent nerve-sparing total parotidectomy that resulted in severe facial disfiguration (Figure 11).

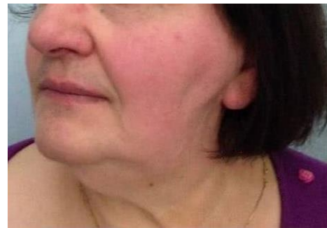

Figure 11. A 59-year-old female with post-parotidectomy facial defect.

The patient asked for cosmetic improvement of the region, but, at the same time, refused to undergo reconstructive surgery. Thus, the HA filler approach was planned to restore facial defects after the parotidectomy procedure and to improve facial eurhythmy. Injection of a 26 mg/mL, polyethylene glycol diglycidyl ether (PEGDE) cross-linked, HA hydrogel (Neauvia Organic Intense Flux, Matex Lab, Lugano, CH) was performed in a subcutaneous layer with cannula. A total of 4.5 mL of HA filler was injected. The treatment resolved the skin depression in the left parotid area (Figure 12).

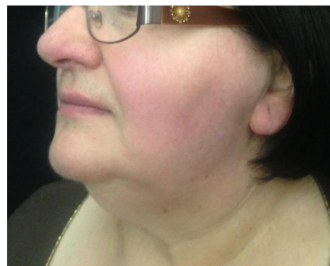

Figure 12. Immediate postoperative result of the same patient shown in Figure 11.

Any further treatment was required. At the 6-month follow-up, the results remained stable.

2.5. Case 5

A 74-old-man was referred to the Department of Craniomaxillofacial Surgery at the University of Campania “Luigi Vanvitelli”, Naples, for evaluation of a maxillary malignant tumor. After tumor resection, facial reconstructive surgery was performed. Superficial temporal artery perforator (STAP) flap was harvested for the restoration of intraoral defect (Figure 13) and the donor site was contextually skin grafted (Figure 14).

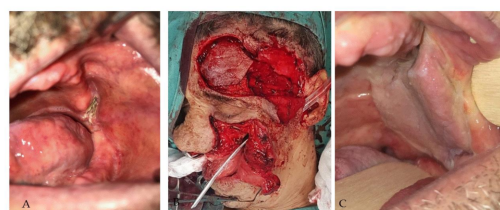


Figure 13. Maxillary malignant tumor (A); intraoperative picture of flap harvesting (B); reconstruction of intraoral defect (C).

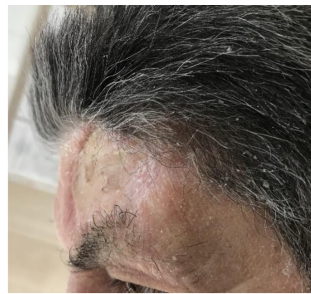

Figure 14. Split thickness skin graft in forehead region.

The flap healed without any complications. Five repeated hyaluronic acid injections of a 20 mg/mL, 1,4-butanediol diglycidyl ether (BDDE) cross-linked HA filler (Hyamira Basic, Nyuma Pharma, Arona, Italy) were performed to reduce the concave aspect of the grafted site. HA injections were performed deep to the bone. A total of 0.2 mL of HA filler was injected during every injective session. The results remained stable at the 9-month follow-up (Figure 15).

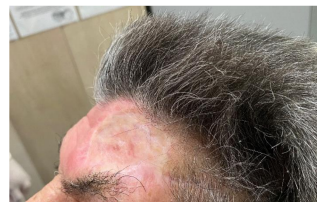

Figure 15. Aesthetical improvement in the forehead region after multiple HA injections: 9-month follow-up results of the same patient are shown in Figure 14.

2.6. Case 6

A 55-year-old man presented to our Craniomaxillofacial Surgery Unit for hard palate carcinoma. Tumor resection and reconstructive surgery were performed (Figure 16).

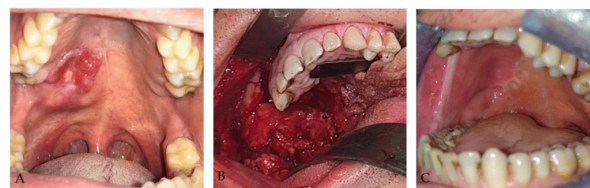


Figure 16. Hard palate carcinoma (A); intraoperative picture of tumor removal (B); reconstruction of intraoral defect (C).

Tunnelized-facial artery myomucosal island flap (t-FAMMIF) was harvested for defect reconstruction. Although the reconstructive outcome was successfully achieved, donor site morbidity was revealed as anesthetic notching in the right cheek region (Figure 17).

According to an accurate preoperative planning, HA was injected in a grid-like fashion with the purpose to restore facial eurhythmy. Biphasic injection of a 20 mg/mL, 1,4-butanediol diglycidyl ether (BDDE) cross-linked, HA filler (Hyamira BASIC, NYUMA PHARM, Arona, Italy) with retrograde technique was performed. A total of 1.8 mL per session was injected, 9 site injections were given. A total of 0.1 mL was injected deeply and 0.1 mL superficially at the same site injection (Figure 18).

This approach was performed with the aim to restore both superficial and muscular layer impaired from the surgery. Two consecutive sessions were required. No functional limitation in the mouth opening was reported. Aesthetic restoration was achieved and the outcomes remained stable at the 8-month follow-up (Figure 19).



Figure 17. Donor site morbidity: anesthetic notching in right cheek region.

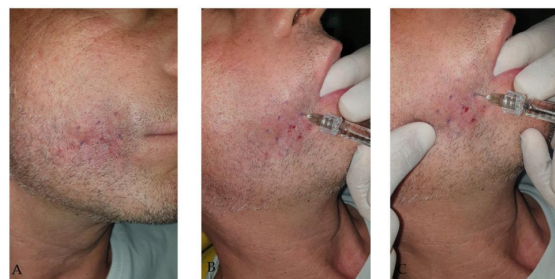

Figure 18. Preoperative planning, HA was injected in a grid-like fashion: preoperative planning (A). Biphasic injection with retrograde technique was performed; nine site injections were given (B,C).



Figure 19. Aesthetical improvement in the right cheek region: 8-month follow-up result of the same patient shown in Figure 17.

Patient and HA filler reconstructive procedure data are summarized in Table 1.

Table 1. Patient and HA filler reconstructive procedure data.

Subject (Case)	Sex	Age	Anatomical Area	Anamnesis	Number of Sessions	HA Amount per Session
1	M	26	Right Malar area	Facial trauma (zygomatic arch fracture)	1	2 mL
2	F	54	Lip	Labial incompetence (permanent implant removal surgery sequelae)	1	3 mL
3	M	34	Temporoparietal area	Facial malformation surgery sequelae	5	4 mL
4	F	59	Left parotid area	Nerve-sparing total parotidectomy sequelae	1	4.5 mL
5	M	74	Left forehead region	Reconstructive surgery sequelae (STAP flap)	5	0.2 mL
6	M	55	Right cheek region	Reconstructive surgery sequelae (t-FAMMIF)	2	1.8 mL

Abbreviations: HA: hyaluronic acid; STAP flap: superficial temporal artery perforator flap; t-FAMMIF: tunnelized-facial artery myomucosal island flap.

3. Results

No relevant complications as impending necrosis, visual loss, or blindness were reported. Bruising and swelling were reported for 48 h after lip injection. Swelling is generally expected after lip injection with HA gel, a naturally water-attracting material, especially when a large amount of the product is used. Bruises are not common when injecting with a surgically-based strategy since most of the vessels are in areas that are not injected. Nevertheless, this complication was observed in 17% of the cases (Table 2).

Table 2. Incidence and percentage of complications related to HA injection performed.

	Impending Necrosis	Visual Loss	Blindness	Bruising	Swelling
Number of Patients	0 (0%)	0 (0%)	0 (0%)	1 (17%)	1 (17%)

At the immediate VAS-scale evaluation, 67% of the patients were “extremely satisfied” and 33% “satisfied” (Table 2). The maximum grade of patient satisfaction referred to the cases of post-parotidectomy facial defect, cheek asymmetry, trauma sequelae, and labial incompetence. In those cases, the improvement after the injective session resulted in better mobility of the lip, restoration of the appropriate projection in the zygomatic region, and adequate softness and eurhythm of the parotideal or cheek region. Patients with post-craniosynostosis surgery asymmetry and forehead loss of substance, reconstructed with skin grafting hampered by stiffness of the skin, correspond to the “satisfied” VAS score. These patients were slightly less satisfied than the others after the first session of injections because the volumes to be created were important and required repeat injections. The VAS score changed to “very satisfied” and to “extremely satisfied” at 6–9 weeks and 3–6 month evaluations (Tables 3–7), contextually to the improvement in tissue flexibility, elasticity, and aesthetic enhancement.

Table 3. Patient satisfaction. Visual analog scale (VAS) was used to assess patient satisfaction immediately after treatment; 100 represents the best possible aesthetic outcome and 0 the worst; 0–74: not satisfied; 75–79: fairly satisfied; 80–89: satisfied; 90–99: very satisfied; 100: extremely satisfied.

VAS Score	0–74	75–79	80–89	90–99	100
Number of Patients	0	0	2 (33%)	0	4 (67%)

Table 4. Patient satisfaction. Visual analog scale (VAS) was used to assess patient satisfaction 6 weeks after treatment; 100 represents the best possible aesthetic outcome and 0 the worst; 0–74: not satisfied; 75–79: fairly satisfied; 80–89: satisfied; 90–99: very satisfied; 100: extremely satisfied.

VAS Score	0–74	75–79	80–89	90–99	100
Number of Patients	0	0	0	2 (33%)	4 (67%)

Table 5. Patient satisfaction. Visual analog scale (VAS) was used to assess patient satisfaction 9 weeks after treatment; 100 represents the best possible aesthetic outcome and 0 the worst; 0–74: not satisfied; 75–79: fairly satisfied; 80–89: satisfied; 90–99: very satisfied; 100: extremely satisfied.

VAS Score	0–74	75–79	80–89	90–99	100
Number of Patients	0	0	0	0	6 (100%)

Table 6. Patient satisfaction. Visual analog scale (VAS) was used to assess patient satisfaction 3 months after treatment; 100 represents the best possible aesthetic outcome and 0 the worst; 0–74: not satisfied; 75–79: fairly satisfied; 80–89: satisfied; 90–99: very satisfied; 100: extremely satisfied.

VAS Score	0–74	75–79	80–89	90–99	100
Number of Patients	0	0	0	0	6 (100%)

Table 7. Patient satisfaction. Visual analog scale (VAS) was used to assess patient satisfaction 6 months after treatment; 100 represents the best possible aesthetic outcome and 0 the worst; 0–74: not satisfied; 75–79: fairly satisfied; 80–89: satisfied; 90–99: very satisfied; 100: extremely satisfied.

VAS Score	0–74	75–79	80–89	90–99	100
Number of Patients	0	0	0	0	6 (100%)

4. Discussion

Despite the current refinement of craniofacial plastic surgical techniques in congenital malformations, tumors, or trauma sequelae, it frequently occurs that, at the end of the surgical course, aesthetic defects persist as asymmetrical of facial volume, which could be a relevant cause of considerable patient dissatisfaction [22–30]. Therefore, plastic and craniofacial applications of mini-invasive techniques should be considered in addition to (or instead of) surgical reconstructive techniques, with the aim of restoring facial eurhythmia.

For instance, the utilization of adipose tissue transfer for the correction of maxillofacial defects after reconstructive surgery [26,27,31], first reported at the end of the 19th century by Neuber [1], has been used for years as an excellent filler during facial enhancement and recontouring, being highly biocompatible and most natural for facial reconstruction. In the late 1980s, Illouz presented liposuction techniques and revolutionized fat transplantation, publishing reports on reinjection of viable fat obtained during liposuction surgery [32–34]. Indeed, with the introduction of liposculpting surgery, fat injection techniques dramatically reawakened [35–41]. In 1987, Klein introduced tumescent anesthesia [42]. This approach enhanced the ability to acquire fresh fat for grafting. There are many clinical settings for which autologous fat is widely used, including congenital, surgical, or traumatic defects, surgical defects, facial hemiatrophy, and idiopathic lipodystrophy [43–45]. In the last decade, autologous fat grafting increased in popularity as one of the most rapidly growing techniques in facial plastic surgery, due to advancement in the procedure of fat cells harvesting and transplantation. For patients who have substantial volume loss, which necessitates global volume replacement, fat is a more ideal filler choice, and several authors have demonstrated excellent reconstructive results [31,44].

An ideal filler material would be readily available, easily acquired, long-lasting, inexpensive, and would not lead to adverse immunologic reactions. Autologous fat meets most of these features. It is soft, biocompatible, lacks toxicity, feels natural, and could be readily harvested and used to improve various reconstructive scenarios. Moreover, adipose-derived stem cells (ADSC) are enclosed within the grafted fat. ADSC are responsible for not only volume restoration, but also improvements in quality of the surrounding tissue.

In fact, recently, structural fat grafting has moved from pure aesthetic surgery to reconstructive, craniofacial, and regenerative medicine [26,27]. In addition to providing volume augmentation and a natural filling effect, injected fat is supposed to have a regenerative ability that improves the texture of the overlying skin [46–48]. Furthermore, fat tissue has shown striking improvement of tissue texture quality, as well as biocellular regenerative potential, due to the large amount of mesenchymal stem cells obtained in the lipoaspirate [47]. The wide availability of adipose tissue combined with a straightforward mechanical protocol to process the fat tissue into a highly-concentrated solution of ADSC, brings regenerative surgery into reconstructive practice [27,48].

However, even if its benefits are simplicity and minimal donor site morbidity, this procedure requires a harvest procedure, additional operative time in harvesting, and decanting phases. Nevertheless, the greatest challenge of structural fat grafting is in maintaining its viability: controversy exists in the literature regarding its durability and the long-term results of lipotransfer are still variable [49]. Furthermore, the fat could not resorb in a uniform fashion and may lead to asymmetries that may require additional procedures for correction [50]. The clinical success of the procedure is referred to the long-term volume maintenance, determined by the ability of the transplanted fat cells to both resist resorption over time and survive in the new environment [49,51]. Various harvesting, preparation, and injection techniques have been proposed to improve fat graft survival [52–54]. However, to date, there is no standard approach with reproducible and predictable outcomes and this issue has led to debate over the ideal lipofilling approach [49,50,53]. Thus, the greatest challenge of fat grafting is in preserving its viability and controversy still exists in the literature, regarding stability and persistence of clinical augmentation with adipose transplants. It is noted that fat volume stabilizes at 3 to 4 months with a subsequent subtle decrease in volume for up to a year after the procedure [52]. The resorption rate reported in the literature ranges from 25% to 90% [55–60]. However, a good result at 6 months was predictive of a lasting correction [61]. Peer reported an average loss of 45% of the free fat implant by 1 year and emphasized the importance of a well-vascularized recipient site [55]. Horl et al. [62] noticed a 55% loss at 6 months, with regular negligible decreases in volume between 9 and 12 months, as documented by magnetic resonance imaging. Rigotti [63] noted that many of the fat cells are disrupted and the ADSC carried with the lipoaspirate repopulate the grafted areas. This could explain both the volume loss and the improvement of texture and volume in the same grafted areas. Current attempts to maximize fat graft amount survival and predictability of engraftment focus on harvesting techniques, fat purification, and infiltration techniques, maximizing the transplantation of ADSC [64–66]. Significant variables include depth and technique of placement, sample washing, syringe and cannula size, anesthesia, expertise in surgical harvesting approach, degree of overcorrection and donor site.

McCurdy et al. [67] analyzed fat cell survival clinically and concluded that insufficient revascularization of grafted adipose cells is one of the main reasons for graft fat resorption among all steps of the technique, such as the harvesting technique, the type of fat, recipient tissue, or internal pressure at the recipient area, which could impair successful engraftment. Moreover, Glogau reported a great degree of individual variation in adipose survival [68]. Authors underline technical characteristics to the prolonged graft survival [65,67–69]. In regard to the donor site choice, the medial side of the thigh and knee, the abdomen, hips, pubis, and gluteal area are the best sites for adipose areas [69]. The donor site should be easily camouflaged and highly lipogenic, and in recent studies, the best results were obtained with the fat tissue, where it is more dense and granular [68]. However, especially when a large amount of product is required for wide reconstructions, obtaining autologous donor fat could be very challenging, especially in thin, cachectic, or malnourished individuals, such as oncologic patients [45,63]. Transplanted fat tissue seems to last the longest in areas with least movement, such as the cranial vault, when compared to placing fat into dynamic facial areas [68–70]. However, clinical experience has shown that the best results were obtained by transplanting fat tissue inside the muscle, followed by transplantation

inside fatty tissue [70]. Histologic studies have confirmed that a low negative pressure technique of aspiration and the use of a rounded cannula causes less trauma, preventing breakage of the fat cells. Moreover, the dull tip could reduce bruising, swelling, pain, and vascular compromise [71].

Overcorrection is usually used to balance the postoperative resorption and Herold [72] stated that it could also enhance the transplanted fat survival rate. In a survey that included 508 plastic surgeons, 87% of those physicians overcorrected with autologous fat grafts [73]. Studies have described the positive effect of platelet-rich plasma (PRP) to enhance survival of fat grafting [74,75]. Even if injectable fillers for facial reconstruction have been extensively promoted, few published reports compare the cost-effectiveness of multiple injectable agents in facial plastic surgery [76].

In a cost-effectiveness analysis for the use of HA filler materials and lipofilling, the cost-effectiveness of fat is described as debatable, due to fatty tissue variability of resorption and the increased recovery-time associated with fat harvesting procedure. On a per-treatment basis, fat grafting appears to be costly when compared with the HA derivatives. However, if the longevity of HA and fat is taken into account, fat is equal or more cost-effective. This evidence could be explained to the fact that the HA filler could require several injections to maintain the same efficacy as fat grafting at 1 year. Fat becomes most cost-effective when used as an ancillary technique to other facial surgery procedures. The surgeon time component is absorbed when performing concomitant surgery. Moreover, the longer patient recovery time associated with the fat grafting procedure is less significant when the patient's recovery is concurrent with other surgical procedures [76]. Moreover, the use of ab HA filler instead of fat, especially for young patients, might add higher total long-term costs. With the improvement of fat grafting techniques, postoperative complications are rare, but could include lumps, bulges, persistent edema, infection, hematomas, and swelling [77,78]. Although cases of embolism and nerve injury have been reported, authors believe that the risk is further minimized using blunt cannulas [77]. Major complications, including blindness or impending necrosis, have been reported following the injection of both HA and autologous fat, but the absence of an antidote as hyaluronidase makes vascular complications more "thoughtful" for lipofilling than HA injection. In reconstructive surgery, it was demonstrated that fat transplantation is a viable option for correcting a post-oncological surgery deformity, even if surgery potentially reduces graft viability secondary to decreased vascularity of the recipient site [79].

A prospective study evaluated and compared HA and autologous fat (AF) injection for reconstructive purposes in case of temporal hollowing after lateral orbital wall decompression [80]. In this study, both injections of HA and AF are demonstrated to be safe and effective. However, a higher total volume of AF than HA was required to achieve the same soft tissue volume. HA was reported to be less time consuming because it did not involve a fat harvesting procedure [80].

Moreover, a review demonstrates the same efficacy, safety, and durability of both HA fillers and AF injections for the treatment of human immunodeficiency virus (HIV)-associated facial lipoatrophy syndrome [81].

It has become popular to use hyaluronic acid (HA)-based fillers to treat facial wrinkles and deep tissue folds [82]. Their space-filling properties are well described both clinically and histologically [83–86], and multiple reports demonstrate the positive effects of HA-based fillers on the dermis [83–88]. HA filler charming features could be related to the relative ease of application, immediate results, and minimal downtime. Because of its effectiveness, safety, and well-tolerated properties, the HA injective technique represents an attractive treatment option, using a minimally invasive technique that could be performed at the office. Thus, facial reconstruction using HA has many advantages when compared to traditional techniques. One outstanding perspective of HA filler injection could be its applications in the reconstructive field. This technique could be applied in any area with a lack of tissue resulting from trauma, tumor resection, and postoperative deformities; it shows immediate, improved visual results, with high patient satisfaction.

Therefore, HA fillers have a high level of aesthetic and functional results in a non-invasive way, with a simultaneous increase of volume and flexibility, without the necessity of a complex reconstructive surgical procedure. The fluidity of HA fillers allows for great precision during injection, which could be performed superficially in a subcutaneous layer as well as deep to the bone, with a restoration in facial projection, such as in the zygomatic area or skull prominence [8].

HA injections, similar to fatty tissue transfer reconstructive outcomes, could achieve outstanding, natural, and symmetrical aesthetical results, with the advantage of avoiding surgical procedures or anesthesia. Moreover, HA fillers have a low adverse event profile, because of the existence of an antidote, hyaluronidase [89–95].

In fact, a unique characteristic of HA is its reversibility via enzymatic digestion with hyaluronidase, a naturally occurring FDA-approved enzyme as a drug dispersion agent. HA filler degradability by hyaluronidase could be considered a safety-feature, giving HA filler a potential edge over other filler materials [91]. Injection technique related-complications, such as overfilling or misplacement, could be reversed by hyaluronidase injection. Nodules, visible or palpable irregularities, occur in only 0.01–0.1% of the cases, and have been attributed to hypersensitivity, foreign body reactions, injection placements, infections, and biofilm development [96,97]. In case of vascular complications, such as impending necrosis or visual loss, the HA filler is unique, in that it can be dissolved with hyaluronidase injections, enhancing its paramount safety features. Because of the varying biochemical properties of the different HA fillers, it should be underlined that each injectable may have a different sensibility to hyaluronidase [95].

Naturally occurring HA degrades with a half-life of 12–24 h while exogenous HA has a half-life of 1–2 h [98]. Therefore, the manufacturing aim is to create an HA filler with increased tissue residency and elasticity, maintaining its biocompatibility. Studies have highlighted that HA content, cohesivity, and crosslinking properties may play a role in the sensitivity and degradability of these fillers to enzymatic degradation [84]. The process of crosslinking accomplishes this purpose. This can be achieved with 1,4-butanediol diglycidyl ether (BDDE), divinyl sulfone, bis(carbodiimide), polyethylene glycol diglycidyl ether (PEGDE) or 1,2,7,8-diepoxyoctane. The degree of crosslinking will enhance the persistence of the HA filler in the tissues, but excessive crosslinking may reduce biocompatibility, causing a foreign-body reaction and encapsulation [99]. Crosslinking will also change the rheological properties of the gel of the HA filler. Harder fillers with a greater degree of crosslinking are more difficult to deliver, causing more discomfort during the injection. Nevertheless, they are able to better resist the dynamic forces of muscle movement and could have longer longevity. Moreover, they may feel firmer under the cutaneous surface and are better suited for volumizing deeper volumetric deficiencies in thicker-skinned individuals. Conversely, softer gels with a lesser degree of crosslinking, are more comfortable for the patients and easier to be injected. Being softer under the skin, they are better suited for the thinner tissue in case of periorbital reconstruction or perioral regions rehabilitation [95,99]. Nonetheless, appropriate filler longevity can provide structural stability and resiliency, which is a requirement for a successful facial reconstruction. Thus, it is important for facial plastic surgeons to consider the delicate balance between stability and degradability when choosing which fillers are best suited for facial restoration.

HA fillers produce lasting results, up to 18 months, depending on individual variability and crosslinking rate, HA concentration, and injective technique [100]. As described in the literature, deep injection could stimulate periosteal stem cells, allowing a semi-permanent effect [101]. In a prospective study by Eccleston [102], 86% of participants treated with HA fillers reported improvement in their lips at 9 months after treatment. Cohesivity is an essential feature of filler implants, defined as the capacity of a gel not to dissociate. This property is certainly important during HA filler distribution into the tissues of the treated area and it is known to affect the lifting capacity of the gels [99]. In addition, one of the most significant—but often overlooked—factor of a successful HA

filler injection is pain control, not only in minimizing discomfort, but also in improving patient satisfaction and reducing procedural downtime. For this reason, local anesthetic, such as lidocaine, has been incorporated in HA fillers as an ancillary active substance with the aim to enhance patient comfort during the injection. Furthermore, lidocaine reduces erythema, bruising, and swelling as a result of its antihistamine property [99]. Together with proper selection of the appropriate reconstructive surgery-based technique, knowledge of rheological properties is mandatory for the selection of the HA filler, with the aim to achieve the planned rehabilitative purposes [95].

According to HA filler rheology, four main parameters should be considered to describe viscoelastic properties of a filler: G^* refers to viscoelastic properties or hardness, G' measures elastic properties, G'' measures viscous properties, and $\tan \delta$ measures the ratio between viscous and elastic properties [103]. It is paramount to use the appropriate filler and the correct technique to achieve an outstanding restorative outcome. Nowadays, HA fillers are no longer only used to address wrinkles, but also to restore volume and facial eurhythmy, according to reconstructive surgery principles. Our strategy of injection is based on surgical concepts, where long-lasting results is the “rule”. In a case of trauma sequelae, the level of injection is not only superficial, but also involves a deep plane as a periosteal layer [101]. Physicians must be guided by the safety of the patient and by an aesthetic approach, respectful of proportions that could be missing after previous surgical procedures or traumatic events. Therefore, modern management is based on volume replacement and contextual tissue tightening. In fact, volumetric restoration is just one aspect of our approach that requires precise evaluation and diagnosis, accurate anatomical study of the patient, and a detailed preoperative marking (Figures 1, 2 and 17) [104]. From a rheological point of view, fillers with high G' have more important lifting effects and are indicated in supraperiosteal boluses to lift and support the tissues, in cases where hard tissue projection is missing. Fillers with moderate G' and G'' , because of their expander capacities, are more designated toward treating the subcutaneous tissue, in case of soft tissue deficiency, such as tumor removal sequelae. In case of midface reconstruction, injecting over the periosteum has the advantage of achieving the correction under the muscles, avoiding the grotesque effect of too much volumetric moving in the dynamic if the filler is mostly placed in a superficial layer. Surgically, this becomes paramount because gels with a higher G' will have better resistance to the dynamic forces incurred with facial muscle movement, providing long-lasting support and volumization [95]. Moreover, gels with a higher G' can cause the Tyndall effect, or visible small blue papules or nodules if injected superficially in the skin [97]. In contrast, in areas that are more static, resistance to deformation by muscle movement is less critical and gels with lower G' are better utilized. These gels are also better suited for areas that need more softness, such as the lips [103].

When volume is obtained by injecting a deep plane with a very precise tool, such as a needle, the trauma of filler deposition on the periosteum is able to activate the periosteal stem cells [101,104] with new tissue formation and a semi-permanent effect. Needle injections only target the bony layer, avoiding the risk of cannulating vessels and, consequently, vascular complications. In the eventuality of subcutaneous injections, required in parotideal area volume restoration, the use of a microcannula is safer (and is recommended) because of the superficial localization of the artery and vein in this region. In this case, the preauricular compartments need both volume enhancement and a tightening effect that could be achieved, with cohesive gels with a moderate G^* .

Planning a complex face reconstruction with fillers requires a double vision: to recollect three-dimensionally the areas of volume loss and to plan the final result before starting, with the appropriate technique that allows minimal side effects. In case of appropriate timing in detection of the malar fracture, a surgical approach of reduction and rigid fixation using plates and screws is the gold standard of treatment. According to trauma surgery principles, it is notorious that malar fracture must be recognized, even if edema could hide the traumatic disfigurement. The absence of functional limitation is not a feature to exclude a fracture suspect. A displaced malar fracture, poorly consolidated several

months after the incident, requires a refracture procedure to replace bone fragments in the correct position, describing a complex maxillofacial surgical procedure to achieve midface eurhythmy restoration. This procedure is surgically very demanding and challenging and could scare the patient (who may just be looking for aesthetic recontouring of the injured facial side, and likely prefers a less invasive approach). Thus, an HA injective protocol was performed with two different types of filler: one with a higher G' to restore malar projection and one with a lower G' , but with a higher G'' to recontour the subcutaneous layer. According to our injective technique, we noted a long-lasting result: after 12 months from the injection, a stable result in the malar arch projection was reported. Even if HA facial fillers usually last about 6–8 months, the achievement of this long-lasting effect could be explained because of deep, periosteal HA injections. As demonstrated by Mashiko et al., this technique provokes an injury and a persisting inflammatory change around the injected HA that activated periosteal stem cells and induced tissue neogenesis, such as fibrosis and ossification [101].

Since separate layers of superficial and deep tissues are injected, we adopted a multi-layer technique for the use of fillers based on surgical anatomy that allows good efficacy, limited use of materials, and optimal longevity.

In case of facial trauma approach, we used Juvèderm Voluma with Lidocaine (Allergan, Irvine, CA, USA) and Juvèderm Volift with Lidocaine (Allergan, Irvine, CA, USA). These fillers—characterized by a mix high and low molecular weight HA chains (Vycross technology) to improve moldability, ease of modeling/shaping, ease of flow during injection, reduce swelling—improve distribution and integration within the tissue, and increase duration of effect [105]. All of these features make these fillers attractive candidates for our reconstructive goals.

In our experience, the concept of facial reconstruction with HA gels is based on surgical logics; thus, the use of the most appropriate product allows the surgeon to achieve optimal results with the minimal amount of product. In fact, we have achieved an excellent reconstruction of an entire malar area with only 1 mL deep to the bone and 1 mL in the superficial layer. Our approach defines a novel reconstructive paradigm shift: in the past, fillers were used for surface treatments and short-lived results, while in our approach, fillers are used mostly to restore both facial symmetry and proportions. In fact, the levels of their injections are the deep planes, and not only the skin; the preoperative planning of injection is based on surgical concepts where maintenance of outcomes is paramount.

Our volume restoration technique helps to limit the amount of filler used, improving the impact of facial sagging and depressions and contextually achieving a lifting effect in malar prominence reestablishment.

It is remarkable that, in this case, the superficial nasolabial compartment is not affected by volume loss, but tends to move medially due to the lack of lateral support caused by the injury in the lateral malar area and the lack of zygoma fixation points. By this injective approach, vertical pillars are created over the bone in order to restore bone support of the malar area [Figure 1]. The lateral to medial sequence of injection helps in achieving a tenting effect, so that less material is needed in the more medial compartment, avoiding an excessive midface projection and respecting symmetry with the contralateral area. Augmentation of the deep medial cheek increases the anterior projection, not completely addressed by lateral redraping, reduces the nasolabial compartment ptosis, and recreates cheek eurhythmy within its natural boundaries and symmetry. The areas of injection are selected precisely according to the reconstructive aim of restoring anatomy. The strategy is based first on deep injections to the periosteal layer, and later on superficial injections in the superficial subcutaneous fat in a multi-plane technique. A total of 0.2/0.4 mL of gel is released in each deep injection in three separate deposits. The gel is released in small bolus and not in a continuous fashion in order to prevent a sausage effect of too much filling. No more than 0.4 mL is released per bolus to avoid the risk of compression over the lymphatic vessels. Once the deep areas are injected, we move to perform the superficial plane treatment. The treatment of the superficial layer is directed only to the area affected

by the traumatic injury. In this case, a microcannula is used in order to prevent bleeding and as a tool to partially undermine the ligamentous areas of the facial retaining ligaments. The access point is located lateral to the lateral canthus of the eye and the cannula is moved inferomedially to target the zygomatic area.

In both areas, a rheologic point of view, gels with high G' have more important lifting effects and are more indicated in boluses over the suprapariosteal layer where they act as pillars to lift and support the tissues, meanwhile fillers with moderate G' are indicated to treat the superficial tissue, where they act as bridges to reconnect the pillars, thanks to their expander capacities. In this case, injecting the deep bone plane was not sufficient to have good results, in terms of natural restoration of volume and projection; thus, 1 mL of product was required to be injected in the superficial plane, allowing for more tightening than volume, especially in the midface area. Thus, according to our technique, the injured and ptotic medial compartment of the superficial cheek fat pad was not injected, avoiding the use of an excessive amount of product. In fact, since the tenting effect was obtained, the treatment of the lateral compartments of the zygomatic arch was enough to improve and restore the whole midface area.

Several techniques to obtain permanent lip enhancements have been developed throughout the years, such as silicone lip implants utilization. Although lip surgery sequelae, as in the case of implant removal, could be obviously addressed surgically, some surgeons prefer not to perform this procedure due to its complexity [106]. In fact, in our patient, a disfiguring cosmetic result was observed after surgical removal of permanent lip implant. Lip incompetence could be an annoying and bothersome condition for the patient because it may cause functional impairment and interfere with several routinely actions, such as sucking or kissing. Moreover, lip incompetence may cause significant changes in lip appearance and may deeply impact patient self-image and quality of life. Several techniques have already been described to correct lip defects [107]. Schweiger et al. [108] reported the use of HA fillers for lip asymmetry correction in cleft lip surgery sequelae. Belyea et al. [79] described the use of HA filler combined with autologous microfat for the management of lip whistle deformity secondary to surgical wedge resections and postoperative radiotherapy in squamous cell carcinoma treatment. Stolic et al. [109] restored with HA injections a lip notch defect after cleft surgery. Recently, Kandhari et al. [110] reported the use of HA fillers to repair congenital and posttraumatic lip asymmetry with accurate and cosmetically satisfactory outcomes. According to our approach, HA filler injection was associated with minimal bruising, swelling, and discomfort. The patient returned to her normal life on the same day of the procedure. Even if this is not a permanent solution, it represents a suitable and non-invasive method, appropriate for those patients who are not candidates for surgery or who refuse invasive procedures.

The lips have always been characterized by sensuality and attractiveness; they are one of the facial areas that draw the most attention and contribute significantly to facial harmony and beauty. Moreover, the lips are central to both verbal and non-verbal communication. Through words or facial expressions, the lips enable one to express feelings and personality.

Thus, one of the most challenging aims in reconstructive techniques is to cherish both beauty and eurythmy of the smile.

As reconstructive aims, younger patients seek to restore their full, naturally plump lips, while middle-aged patients wish to restore volume and re-establish their natural lip shape. As the HA injective techniques vary substantially between individual patients, we suggest to approach every case according to anatomical knowledge, with surgical skills and tailored treatments for each patient.

When assessing treatments for highly dynamic areas, such as the lips, in addition to the appropriate technique, we believe it is crucial to choose the appropriate amount of HA filler that can accompany and respect natural lip movements, which is fundamental to achieving natural-looking results and morphofunctional restoration.

For this reason, we used a 15 mg/mL, BDDE cross-linked, HA filler (Teosyal PureSense Redensity II, Teoxane, Geneva, Switzerland). Thanks to the balance between stretch and

volumizing capacities, we selected an appropriate product in this dynamic facial area, based on high stretch capacity, to achieve natural-looking lip eversion, and on the high malleability of the product, which enables easy filler positioning and molding under the labial mucosa. Choosing a filler with this property is crucial in a complex case, such as lip reconstruction. Even if the amount required was high, we reached lip restoration with 3 mL of product, achieving a natural-looking lip reconstructive outcome.

Consistently with facial plastic surgery principles, the current trend in reconstructive surgery is to obtain facial reconstruction to respect facial subunit eurhythmmy. To do so, it is essential prior to performing any HA injection treatment to implement facial assessment based on a sound understanding of facial anatomy, as well as deep knowledge of the dynamic movements of the face. This principle is of paramount importance, especially in reconstruction of the lips region.

Surgeons must also select an adapted and efficient technique to inject the gel in the right location to enable it to follow the natural movements of the area. For this purpose, it will be important to choose HA fillers with appropriate rheological characteristics and the appropriate amount of product. The choice of an inappropriate product or excessive injection of a product could lead to undesirable results (i.e., of disfiguring and functional impairment).

Our approach was developed to allow for optimal results based on these principles: anatomical knowledge, facial expression analysis, customized injection, rheological property, and physicochemical profile of HA filler.

Surgical expertise, combining the right products at the proper injection depth with the appropriate injection technique, and filler amount, are crucial factors in achieving predictable, natural-looking, and unique reconstructive results, while preserving the dynamic movements of the lips and smile area.

Because the amount required (3 mL) was remarkable to obtain eversion of the inferior lip—to recruit tissues to restore labial competence, we had a choice of malleable, resilient, and dynamic gels reminiscent of natural HA, with notable strength properties, and moldability under dynamic conditions.

Thus, we used a 15 mg/mL, 1,4-butanediol diglycidyl ether (BDDE) cross-linked, HA filler (Teosyal PureSense Redensity, Teoxane, Geneva, Switzerland) that had the property of long HA chains, preserved natural and mobile interactions among long HA chains, and a low amount of crosslinked BDDE. Moreover, the filler's ability to adapt to continuous external constraints and return to the original shape without breaking, and to resist repeated and increasing constraints, makes it more suitable in the reconstruction of a dynamic area, such as the lips.

Furthermore, this hyaluronic acid filler is formulated with lidocaine, allowing minimal discomfort during injection, and could be injected slowly at low pressure. All of these features make it possible to meet the specific requirements of this mobile facial area, and we elect this filler as a good candidate for lip restoration.

Based on our experience, minimally invasive HA injection can be useful in patients with post-parotidectomy facial volumetric deficits because it achieves aesthetic enhancement without significant morbidity. However, more cases are necessary to confirm our encouraging findings. Parotidectomy is a common procedure performed in a highly cosmetic region and it is poised to benefit from advances in volume restorative techniques [111]. Even if many approaches have been proposed, the treatment of choice for post-parotidectomy deficit restoration is still missing [112], and invasive surgical procedures are related with the risk of facial nerve injuries. These reconstructions include a sternocleidomastoid flap rotated into the defect and elevating a superficial musculoaponeurotic flap prior to performing parotidectomy. These reconstructive options help in postoperative facial symmetry improvements, reducing contour asymmetry, especially in cases of total parotidectomy [111]. Multiple microsurgical reconstructive options exist for soft tissue reconstruction. Anterolateral thigh free flaps have been the “mainstay” of treatments due to variability in their size and shape, and the presence of large vessel calibers available

for microvascular anastomosis [113]. Other options include the latissimus dorsi free flap, which is difficult to harvest, a high postoperative donor site morbidity, and a superficial inferior epigastric artery free flap, which has much smaller caliber vessels [112].

Because of the rising interest in minimally invasive techniques for aesthetic and functional head and neck surgeries, Curry and Clauser proposed autologous fat graft reconstruction as a means of restoring post-parotidectomy facial defects [114,115].

The usefulness of minimally invasive HA injections for the treatment of post-parotidectomy facial defects is supported by the significant, subjective improvements after treatment. The rationale underlying the potential effectiveness of HA injections is that this technique should fill the gap between the skin and the residual parotid lodge tissue, restoring the appropriate facial volume and contouring. Thus, the injections have a good aesthetic impact, as they fill the depression left by parotid gland excision, as shown by the post-operative VAS in the treated case. This technique could be performed without any anesthesia; it is well tolerated, safe, and does not lead to significant morbidity or facial nerve injury. Nevertheless, patients have to be informed that the procedure may need to be repeated to achieve a definitive result.

The parotid area is injected superficially under the skin in the subcutaneous tissue overlying the parotideomasseteric fascia with microcannula. Then, the cannula is cautiously inserted underneath in a plane parallel to the skin and slowly directed inferomedially in fan-like movements. The aim is to deposit the gel in the subcutaneous layer in the region delimited cephalad by the zygomatic arch and caudad by the region between the angle of the mandible and mastoid process, just above the deep cervical fascia. The end point of the treatment is the elimination of the concavity of the area injured from the previous surgery and the achievement of a uniform or even slightly convex contour among the zygomatic arch, mandibular angle, and sternocleidomastoid muscle. The superficial subcutaneous layer is mostly important in the parotid area where it contributes to the contour and the general shape of the face. An optimal deposition of the material with cannula requires two ports of entry, one in the pretragal area and the other located caudally in front of the earlobe. Working superficially with a cannula in this area prevents damage to the numerous vessels in the area and to the branches of the facial nerve located under the subcutaneous layer and superficial musculoaponeurotic system (SMAS). According to our reconstructive purposes, we need only a tightening effect that is commonly achieved with cohesive gels with moderate G' and G'' , used in order to have good spreading of the material throughout the compartment, with a filling effect potentially improvable with a delicate massage. Thus, a 26 mg/mL, PEGDE cross-linked, HA hydrogel (Neauvia Organic Intense Flux, Matex Lab, Lugano, Switzerland) was used in order to spread evenly in the subcutaneous tissue and to not be “heavy” on the skin of the area. In fact, a biomimetic filler PEGDE crosslinked was used—a new technology able to give products a high level of biocompatibility, an excellent rheological ratio, high tolerability profile, and optimal biointegration in the connective tissue of the skin [94,95]. These features make this filler suitable for our reconstructive approach. In fact, this gel distributes finely in the interstitial tissue among constitutive structures of the hypodermis and dermis, even into the smallest spaces between collagen fibers, always preserving the structural integrity of the skin.

Furthermore, no evidence of inflammation surrounding the implant was reported and this allowed a safety profile of adverse effects in an area with a high density of facial nerve fibers. The high concentration of HA and low viscoelasticity enhanced the volumetric results in shaping the injected area in a natural way, treating a region of different consistency as the parotid area. Furthermore, according to the balanced crosslinking degree, this filler was highly adaptive to the tissue, which helped to volumize the anatomic area. Moreover, in the present case, the use of a temporary reconstructive solution led to the search for a gel with outstanding advantages for longevity. The metabolism of PEGDE, according to its properties, reduces the action of the proteolytic enzymes as hyaluronidase increases the duration of the implant [94], with a lower need to repeat the injection after the first treatment, as demonstrated by the stable result at the 6-month follow-up.

In case of craniomaxillofacial malformation, a surgical approach greatly improves the morphological appearance, but the result could be aesthetically incomplete. Persing [25,116] attributes one reason of postoperative depression to the muscular displacement with mastication and states that the temporal muscle reattachment to the underlying bone is not enough to prevent subsequent dislocation and, thus, volumetric asymmetry or hollowing of the region. The long-term contour of the skull vault after surgical remodeling is often unpredictable and bone reshaping could result in irregularity and depression. Once this occurs, options for reconstruction include autogenous bone grafting, which suffers from a high rate of resorption [23,117]. Many different materials have been used to repair craniofacial bone defects; methyl methacrylate and hydroxyapatite cement (HAC) are two of the most commonly used. Despite the large use of methyl methacrylate, its effectiveness and unlimited supply, methyl methacrylate cranioplasty has several disadvantages, e.g., a highly exothermic reaction up to 100 °C resulting in tissue necrosis [118]. Moreover, methyl methacrylate leads to an inflammatory reaction with a foreign-body response, fibrous encapsulation [119], and infection rate from 1% to 16% [120,121]. Even if HAC causes no toxic reactions, releases no heat, and does not cause a foreign body reaction or fibrosis, studies have shown an important inflammatory reaction [122] and a risk of infections acting as a nidus for contamination, with a significantly increased risk of a postoperative wound dehiscence [123]. HA could overcome the significant limitations of those materials. These reasons have prompted us to treat craniosynostosis surgery sequelae in a minimally invasive way by HA injection with the aim to perfect the morphological result restoring missing volumes and facial eurhythmmy immediately after the procedure.

The temporoparietal region was injected in the deep plane, directly to the bone with vertical pillars. According to the reconstructive aims, a strong gel with a high G' was used in order to obtain the maximum vertical expansion of the tissue and no lateral spread of the material. The volume required for cranial reconstruction is obtained from injecting the deep plane and particularly the bony layer where trauma and deposition of the gel on the periosteum are able to induce periosteal stem cells activation [101], with new tissue formation and almost a permanent effect. Reaching the bony layer is faster and easier with a needle that provides the surgeon with perfect control of the release of the gel. With an accurate anatomical study of the patient and a preoperative marking, needle injections target only the bony plane, an avascular layer allowing injections without bleeding.

A three-dimensional remodeling of the present case requires an important volume enhancement. Thus, every area of injection should be treated in a step-by-step fashion in order to achieve good visual impact. Therefore, we planned a multistep treatment; the first correction was further improved by four subsequent touch-up treatments. For areas such as the temporoparietal cranial vault, where the product can be placed against the bone for projection, a higher G' product will provide a greater advantage over a lower G' product, because it will have greater resistance to the compressive forces inherent in the deeper injection plane. To achieve the planned outcomes, the choice of the proper product is paramount.

In this case, we used a 28 mg/mL, polyethylene glycol diglycidyl ether (PEGDE) cross-linked, HA hydrogel (Neauvia Organic Intense, Matex Lab, Lugano, Switzerland), focusing on an innovative and advanced crosslinking technology based on the use of PEGDE. This crosslinker shows a peculiar matrix structure resembling a spider web, a feature closely related to the category of monophasic gels. PEGDE is a difunctional, highly water-soluble polymer, nontoxic, and nonimmunogenic [94]. Its chemical structure makes the final polymeric organization of the filler less rigid than other crosslinking chemical agents [94,95]. Moreover, the ether bonds formed during the crosslinking reaction are particularly stable in the physiological conditions of facial deep layers [95]. Moreover, this filler has an excellent cohesivity profile, defined in the rheological context as the ability to resist compression and elongation stress. The high values of G' obtained for this 28 mg/mL HA hydrogel indicated that these gels were able to resist deformation to a great extent. Thus, the physicochemical characterization, the rheological, and cohesivity

properties were ideal in respect to our clinical considerations, injection techniques, and reconstructive purpose.

In complex facial plastic reconstructive procedures, after major oncological surgery, the perforator-based propeller flap is a versatile armamentarium for intraoral tissue reconstruction. According to the reconstructive surgery principles, it could be necessary to replace the donor site with skin grafting. In the forehead region, it could result in a loss of projection and eurythmy of this area because of the different thicknesses between the forehead region and the grafted area. This disparity has prompted us to use HA injection as a volume enhancer, reporting a noteworthy tissue projection after HA injection. Moreover, seven weeks after HA injections, we noticed an exceptional improvement in tissue elasticity; it could be explained from the HA viscoelastic properties [124]. In fact, HA stimulates fibroblasts proliferation [125,126] and decreases collagen contraction [127,128]. Furthermore, it is proved in mice that extracellular matrix is reshaped after local injection of HA with an optimization of collagen fibers [129]. Moreover, Pliwal et al. demonstrated in rats that HA locally stimulates the production of several components of the dermal extracellular matrix, increasing the production of elastin, promoting genetic reassessment, and improving a correct collagen assembly [130]. It was demonstrated in humans that HA injections increase local vascularization and epidermal thickness contextually to collagen proliferation and dermal fibroblasts production [131,132]. Another reason for tissue flexibility improvement after local injection of HA could be due the local hydration linked to the strong hydrophilicity of HA [133,134]. Collecting water particles, HA filler increases soft tissue volume, providing greater elasticity [133]. Once surgical sites were completely healed, we approached the surgical sequela of the donor site performing sub and supraperiosteal injections of a reticulated, 20 mg/ mL cross-linked HA filler (Hyamira BASIC, NYUMA PHARM s.r.l., Arona, Italy). According to the area to restore, a preoperative planning and a multi-step injective technique was scheduled with the aim to define the proper amount of HA filler to be injected. Thus, 0.2 mL of HA per session were used, a total of five sessions were performed. In the presence of a hard tissue area and volumetric impairment, such as in the case of split-thickness skin grafting, the first HA injection improved flexibility and elasticity, but acquired moderate volume enhancement, because the tissues were still a little deformable. During the first injective session, great resistance was noted injecting HA, due to the scar tissue developed under the skin graft. From the second injection session, we noticed a relevant volumizing effect because the tissues were softened and could have been more easily expanded due to their augmented flexibility. After each session, a progressive volumization of the area was reported. Moreover, the skin graft, at the beginning completely attached and not mobile from the underlining frontal bone, showed progressive improving in softness and mobility. At the nine-month follow-up, the treated area showed stable results, both in terms of volumization and softness.

To enhance the concave appearance and to obtain satisfying outcomes, we performed perpendicular HA injections with a needle. Our experience confirms that the viscoelastic HA properties enhances skin graft texture, volume, and elasticity, stimulating fibroblasts proliferation [130,133], increasing collagen production, and decreasing collagen contraction [131]. Moreover, the hypothesis of HA filler volumetric enhancement could be based on the concept that the volumizing effects could also result from tissue induction of periosteum-resident stem cells. One clinical pattern to explain our hypothesis is cauliflower ear, a condition characterized by hypertrophied tissue developed after repeated traumatic auricular hematoma [135]. The chondrogenic potential of the perichondrium, after hematoma formation and perichondrium detachment, activated perichondrium-resident stem cells that may fill the dead space with chondrogenesis, fibrosis, and ossification. Moreover, new bone formation at the edge of a tissue expander was experimentally demonstrated in animal model to be induced by activated periosteal stem cells [136,137]. Thus, to enhance the concave appearance and to obtain satisfying outcomes, we performed perpendicular HA injection with a needle deep to the bone, to stimulate the activation of periosteum resident stem cells. Nine months after the injections, a stable more concave appearance of the defect

was noted and the skin graft appeared softer and more mobile when compared to the pre-injection time. We suppose that these features could be secondary to the improvement induced by our technique and by the physiochemical properties of HA injected into the fibrotic tissue between the skin graft and the frontal bone.

Palatal defects, typically composite in nature, are challenging to reconstructive surgeons due to the lack of availability of local tissue to fill the gap [134,138]. Moreover, surgical repair aims to use a flap to restore function with minimal donor-site compromise. Furthermore, a general consensus on the protocol of treatment is lacking [139,140]. Obturators could be considered as an easy and readily available option, but the resulting halitosis and tiring maintenance of the device have consistent underrated impacts on the quality of life of those patients.

Microvascular reconstruction, as anterolateral thigh perforator flap (ALT), forearm free flap (FFF), and medial sural artery perforator flap (MSAP) are reported to be the gold standards for surgical reconstruction due to their widespread acceptance, popularity, versatility, and reliability [141]. Moreover, microvascular flaps, especially for intraoral defects, make “like-with-like” reconstruction difficult [142], and represent procedures that necessitate long surgical time, utilization of intensive care unit (ICU), amplified rates of revision surgery, prolonged hospitalization, and a considerable donor site morbidity. For example, FFF donor-site compromise is reported as a delayed graft uptake, numbness, chronic pain, aesthetic impairment, reduced pinch strength, and wrist extension [134–144].

There are several opinions regarding the balance between functional rehabilitation and donor-site scarring, which invoke a sense of disinclination in the reconstructive surgeon [145].

Local flaps as tunnelized-facial artery myomucosal island flap (t-FAMMIF) are attempted with the aim of achieving the results desired with marginally invasive and time-friendly techniques [146]. Palatal defects require thin and pliable flaps that do not add to the bulk of the palate, providing a taut and well-contoured palate suitable for satisfactory articulation and mastication. Thus, t-FAMMIF was considered because of the favorable tissue quality and flexibility (in terms of composition and reliable anatomy), in cases with moderate-sized palatal defects. Unfortunately, donor-site morbidity following t-FAMMIF harvest could demerit the utility of this viable flap and affect the career of a facial plastic surgeon. Trismus, partial mouth opening limitation, scar contracture, and cheek deformity lead to uncertainty in regard to being the first choices for such defects. Moreover, most of the studies could not emphasize on the reconstructive aspect of the donor-site according to its significance in a patient's routine life [143–146]. According to our experience, HA injection was found to be a viable tool for local restoration, being an office-based therapy with no complaints of a painful treatment. This approach could play a vital role in postoperative rehabilitation, not only for aesthetic enhancement, but also for avoiding scar contractions of the donor site. In fact, the prime downside of this flap was found in articulation studies that conveyed noticeable deflections from the normal [144–146]. This evidence was not reported in our experience. Thus, patients undergoing palatal reconstruction with t-FAMMIF should be enrolled in postoperative restoration therapy for HA injective sessions, depending on the size of the cheek defect. We advocate early initiation of a tailored postoperative therapy and donor-site management protocols with minimally invasive techniques, to achieve successful, aesthetic, and functional rehabilitation.

With a drastic increase in the popularity of non-surgical techniques, it is very important to approach post-surgical sequelae in patients seeking enhancement with a soft modality, respectful of their facial anatomy, eurhythm, and function. The reconstructive surgeon must be guided by the safety for the patient, and by an aesthetic approach respectful of proportion and morphology. As in the present case, a proper approach is based on volume replacement, tissue tightening, and a multi-layer rehabilitation technique to reconstruct both the subcutaneous and muscular layer involved in the myomucosal flap raising. In fact, volumetric restoration is just one aspect of the approach [146] and it is necessary that physicians educate patients to understand the strategy of a treatment that requires

precise evaluation and diagnosis. Moreover, in cheek restoration after reconstructive surgery, functional exercises of mouth openings could better the results, by preventing the development of thick and wide scar tissues and molding the injected HA gel.

A 20 mg/mL, BDDE cross-linked, viscoelastic HA filler (Hyamira BASIC, NYUMA PHARM, Arona, Italy) was formulated to guarantee a “high grade” of natural-looking results. It integrates perfectly in the tissues, thanks to its rheological characteristics, keeping facial volume at the correct level, both statically and dynamically, making this filler the ideal material to achieve our reconstructive aim. Moreover, the characteristics of this HA gel allow filler reabsorption into the tissues with distribution kinetics that depend strongly on its infiltration depth and technique.

Even if this filler complies with our reconstructive needs and guarantees immediate (and long-time) safety, two consecutive sessions were due to a progressive strategy of restoration from the deep muscular layer to the surface. This approach was planned to prevent (i) excessive modification in facial symmetry; (ii) too much product amount; and (iii) side effects, such as swelling and bruising. In this case, each compartment required a different layer of injection in order to restore the single anatomical subunit in both the superficial subcutaneous and the deep muscular layer. Thus, according to our experience, biphasic injection with a needle was the most appropriate technique used. After injections to the deep muscular plane, no massage is needed and, indeed, it is useful not to touch the gel to prevent the risk of migration. In the subcutaneous plane, on the contrary, a moderate massage can help in spreading the gel laterally to improve its capacity of expansion.

However, there are some potential limitations to the study. Since the study represented only six consecutive patients, we recognize the weakness of our small sample size. Moreover, the retrospective study design, including the potential selection bias, is acknowledged.

We believe that reconstructive techniques using HA filler injections would contribute greatly to the reconstructive plastic surgeon’s armamentarium. This approach provides significant enhancement in restoring facial volumetric eurhythmmy using a non-surgical minimally invasive hyaluronic acid filler-based technique. In addition to an appropriate surgical reconstructive technique, HA fillers, injected to restore the eurhythmmy of an asymmetrical area of the face, immediately allow for improved visual results.

5. Conclusions

This minimally invasive approach (Minimally invasive reconstructive approach using HA filler injections) provides a high level of aesthetic enhancement, improving patient satisfaction, and increasing volume and flexibility with enhancement in facial morphology and shape. In our experience, no major complications, such as impending necrosis or visual loss, were described. Mild, transient, and reversible side effects, such as bruising and swelling, were reported for 48 h after lip injection.

The knowledge of filler rheology and physicochemical properties, including HA concentration, polymer chain length, crosslinking degree, or crosslinking technology, will significantly influence product selection and indication, according to the most appropriate injective technique. Facial filler development is an advancing field; the purpose is to refine products to maximize efficacy and minimize adverse effects. With the ability to manipulate the biochemical compositions of the inherent characteristics of fillers, it has become apparent that no singular filler could be used for every reconstructive purpose. Instead, different fillers are emerging as unique products best suited for the rehabilitation purpose, given the various filler characteristics, facial plastic surgeon needs, and the demanding requirements to achieve facial reconstruction. In conclusion, we believe that there is a need for further randomized clinical trials, considering the type of HA that would be more suitable for a reconstructive approach. Thus, differentiating products by their rheologic and physicochemical properties may serve as a useful way to select which products are most suitable for a given surgical need.

The ability to find trends between a product's rheology and physicochemical parameters appears to be strongest among products of similar concentrations and those produced by the same technology, but not between manufacturing technologies.

Although HA physicochemical properties are valuable means for product differentiation, the lack of standard measurement techniques among different researchers remains as an obstacle for the discovery of the ideal temporary filler.

Moreover, although there is a wide body of literature describing how such data can be used to characterize different HA products, there are very few studies that correlate in vitro measurements with in vivo performances. Moreover, there are potentially many different properties that impact product characteristics, and future studies in this field may help to correlate product properties with clinical reconstructive experiences.

Ultimately, there are no existing HA fillers for all of the technical surgical skills learned through practical experiences. In this respect, we aim to provide our reconstructive experience with specific product attributes and techniques as they relate to our rehabilitation approach. Moreover, we hope that the data and discussion topics presented represent a preliminary step in the reconstructive ladder in selecting the best suited injective approaches to the reconstructive needs of each patient. The concept of an HA filler application could be a frontier that may be applicable to other areas of reconstructive facial plastic surgery.

Author Contributions: Conceptualization, F.C.; methodology, G.C.; validation, A.C., P.B., and R.F.; formal analysis, L.R.; investigation, G.A.; resources, G.T.; data curation, G.C.; writing—original draft preparation, F.C.; writing—review and editing, A.C.; visualization, P.B., R.F., L.R., and G.A.; supervision, G.T., F.C., and G.C.; project administration, N.S. and F.C. All authors have read and agreed to the published version of the manuscript.

Funding: This research received no external funding.

Institutional Review Board Statement: All procedures performed in studies involving human participants were in accordance with the ethical standards of the institutional and national research committee, with the 1964 Declaration of Helsinki, and its later amendments or comparable ethical standards.

Informed Consent Statement: Informed consent was obtained from all subjects involved in the study. Written informed consent was obtained from the patients to publish this paper if applicable.

Data Availability Statement: Not Applicable.

Conflicts of Interest: The authors declare no conflict of interest.

References

1. Neuber, G.A. Fettransplantation. *Chir. Kongr. Verhandl. Dsch. Gesellch. Chir.* **1893**, *22*, 66.
2. Jones, D.H. Semipermanent and Permanent Injectable Fillers. *Dermatol. Clin.* **2009**, *27*, 433–444. [\[CrossRef\]](#)
3. Broder, K.W.; Cohen, S.R. An Overview of Permanent and Semipermanent Fillers. *Plast. Reconstr. Surg.* **2006**, *118*, 7S–14S. [\[CrossRef\]](#)
4. Chirico, F.; Bove, P.; Fragola, R.; Cosenza, A.; De Falco, N.; Giudice, G.L.; Audino, G.; Rauso, G. Biphasic Injection for Masseter Muscle Reduction with Botulinum Toxin. *Appl. Sci.* **2021**, *11*, 6478. [\[CrossRef\]](#)
5. Rauso, R.; Tartaro, G.; Chirico, F.; Zerbinati, N.; Albani, G.; Rugge, L. Rhinofilling with hyaluronic acid thought as a cartilage graft. *J. Cranio Maxillofac. Surg.* **2020**, *48*, 223–228. [\[CrossRef\]](#)
6. Öhrlund, J.Å.; Edsman, K.L. The myth of the “biphasic” hyaluronic acid filler. *Dermatol. Surg.* **2015**, *41*, S358–S364. [\[CrossRef\]](#) [\[PubMed\]](#)
7. Borrell, M.; Leslie, D.B.; Tezel, A. Lift capabilities of hyaluronic acid fillers. *J. Cosmet. Laser Ther.* **2011**, *13*, 21–27. [\[CrossRef\]](#)
8. Rauso, R.; Giudice, G.L.; Zerbinati, N.; Tartaro, G. Hyaluronic Acid Injections as Nonsurgical Alternative in case of Delayed Diagnosis of Malar Arch Fracture: Case Report and Literature Review. *Case Rep. Surg.* **2019**, 1360741. [\[CrossRef\]](#)
9. González, N.; Goldberg, D.J. Update on the Treatment of Scars. *J. Drugs Dermatol.* **2019**, *18*, 550.
10. Kavoussi, H.; Kavoussi, R. Revision of a depressed scar across a relaxed skin tension line by punch elevation, filler injection, and fractional CO₂ laser. *Acta Dermatovenerol. Alp. Pannonica Adriat.* **2019**, *28*, 129–130. [\[CrossRef\]](#)
11. Sahan, A.; Tamer, F. Restoring facial symmetry through non-surgical cosmetic procedures after permanent facial paralysis: A case report. *Acta Dermatovenerol. Alp. Pannonica Adriat.* **2017**, *26*, 41–42. [\[CrossRef\]](#)
12. Rauso, R.; Albani, G.; Salini, C.; Rugge, L.; Chirico, F.; Tartaro, G. Continuum: Late Onset Complications Secondary to Polyacrylamide Hydrogel-Based Filler for Rehabilitation of HIV-Related Facial Lipoatrophy. *Aesthetic Surg. J.* **2019**, *39*, NP152–NP155. [\[CrossRef\]](#)

13. Rauso, R.; Califano, L.; Rugge, L.; Chirico, F.; Tartaro, G. Late onset complications secondary to polyacrylamide hydrogel-based filler for rehabilitation of HIV-related facial lipoatrophy. *Aesthetic Surg. J.* **2018**, *38*, N170–N174. [\[CrossRef\]](#)
14. Rauso, R. 5-Year Study of a Polyacrylamide Hydrogel-Based Filler for Rehabilitation of HIV-Related Facial Lipoatrophy. *Aesthetic Surg. J.* **2015**, *35*, 1021–1029. [\[CrossRef\]](#)
15. Ho, D.; Jagdeo, J. Safety and Efficacy of a Volumizing Hyaluronic Acid Filler for Treatment of HIV-Associated Facial Lipoatrophy. *JAMA Dermatol.* **2017**, *153*, 61–65. [\[CrossRef\]](#)
16. Jagdeo, J.; Ho, D.; Lo, A.; Carruthers, A. A systematic review of filler agents for aesthetic treatment of HIV facial lipoatrophy (FLA). *J. Am. Acad. Dermatol.* **2015**, *73*, 1040–1054.e14. [\[CrossRef\]](#) [\[PubMed\]](#)
17. Chirico, F.; Rauso, G.; Fragola, R.; Giudice, G.L.; Pinto, L.; De Falco, N.; Cosenza, A.; Rugge, L.; Sgaramella, N.; Tartaro, G. Complications Following Non-Surgical Aesthetic Treatments in HIV+ Patients Receiving Antiretroviral Therapy: A 12-Years Experience. *Appl. Sci.* **2021**, *11*, 4059. [\[CrossRef\]](#)
18. Franchi, G.; Neiva-Vaz, C.; Picard, A.; Vazquez, M.P. Facial Injections of Hyaluronic Acid-Based Fillers for Malformations. Preliminary Study Regarding Scar Tissue Improvement and Cosmetic Betterment. *Ann. Chir. Plast. Esthet.* **2018**, *63*, 197–204. [\[CrossRef\]](#) [\[PubMed\]](#)
19. Inbal, A.; Lemelman, B.T.; Millet, E.; Greensmith, A. Tissue Expansion Using Hyaluronic Acid Filler for Single-Stage Ear Reconstruction: A Novel Concept for Difficult Areas. *Aesthetic Surg. J.* **2017**, *37*, 1085–1097. [\[CrossRef\]](#) [\[PubMed\]](#)
20. Kajdic, N.; Spazzapan, P.; Velnar, T. Craniosynostosis—Recognition, Clinical Characteristics, and Treatment. *Bosn. J. Basic Med. Sci.* **2018**, *18*, 110–116. [\[CrossRef\]](#) [\[PubMed\]](#)
21. Dempsey, R.F.; Monson, L.A.; Maricevich, R.S.; Truong, T.A.; Olarunnipa, S.; Lam, S.K.; Dauser, R.C.; Hollier, L.H., Jr.; Buchanan, E.P. Nonsyndromic Craniosynostosis. *Clin. Plast. Surg.* **2019**, *46*, 123–139. [\[CrossRef\]](#) [\[PubMed\]](#)
22. Gosain, A.K. Hydroxyapatite Cement Paste Cranioplasty for the Treatment of Temporal Hollowing After Cranial Vault Remodeling in a Growing Child. *J. Craniofac. Surg.* **1997**, *8*, 506–511. [\[CrossRef\]](#)
23. Grant, J.H., 3rd; Roberts, T.S.; Loeser, J.D.; Gruss, J.S. Onlay Bone Graft Augmentation for Refined Correction of Coronal Synostosis. *Cleft Palate Craniofac. J.* **2002**, *39*, 546–554. [\[CrossRef\]](#)
24. Hollier, L.; Stal, S. Calcium Phosphate Cement Cranioplasty: Clinical and Radiographic Follow-up. *Int. J. Plast. Surg.* **2003**, *2*, 1–6.
25. Persing, J.A.; Mayer, P.L.; Spinelli, H.M.; Miller, L.; Criscuolo, G.R. Prevention of “Temporal Hollowing” After Fronto-orbital Advancement for Craniosynostosis. *J. Craniofac. Surg.* **1994**, *5*, 271–274. [\[CrossRef\]](#)
26. Clauser, L.C.; Tieghi, R.; Consorti, G. Parry–Romberg syndrome: Volumetric regeneration by structural fat grafting technique. *J. Cranio Maxillofac. Surg.* **2010**, *38*, 605–609. [\[CrossRef\]](#) [\[PubMed\]](#)
27. Clauser, L.C.; Tieghi, R.; Galiè, M.; Carinci, F. Structural fat grafting: Facial volumetric restoration in complex reconstructive surgery. *J. Craniofac. Surg.* **2011**, *22*, 1695–1701. [\[CrossRef\]](#)
28. Petrone, P.; Trecca, E.; Cassano, M.; Quaranta, N.A.; Fiorella, M.L.; De Santis, V.; Ressa, M.; Dalena, E.; Dalena, P.; Fortunato, F.; et al. Effects of ischemic preconditioning with resveratrol on epigastric rat flap: New perspectives for head and neck reconstruction. *J. Biol. Regul. Homeost. Agents* **2019**, *33*, 1603–1607.
29. Portincasa, A.; Cecchino, L.R.; Trecca, E.; Lembo, F.; Annacontini, L.; Ciancio, F.; Corsi, F.; Cassano, M.; Parisi, D. A rare case of Brooke-Spiegler syndrome: Integrated surgical treatment of multiple giant eccrine spiradenomas of the head and neck in a young girl. *Int. J. Surg. Case Rep.* **2018**, *51*, 277–281. [\[CrossRef\]](#)
30. Trecca, E.M.C.; Adunka, O.F.; Mattingly, J.K.; Hiss, M.M.; Cassano, M.; Malhotra, P.S.; Riggs, W.J. Electrocochleography Observations in a Series of Cochlear Implant Electrode Tip Fold-Over. *Otol. Neurotol.* **2020**, *42*, e433–e437. [\[CrossRef\]](#)
31. Portincasa, A.; Trecca, E.; Ciancio, F.; Annacontini, L.; Bufo, P.; Fortunato, F.; Cecchino, L.R.; Parisi, D.; Cassano, M. The role of lipofilling in reconstructions with dermal regeneration template: Clinical and histological assessment. *J. Biol. Regul. Homeost. Agents* **2018**, *32*, 171–176. [\[PubMed\]](#)
32. Illouz, Y.G. The fat cell ‘graft’, a new technique to fill depressions. *Plast. Reconstr. Surg.* **1986**, *78*, 122–123. [\[CrossRef\]](#) [\[PubMed\]](#)
33. Illouz, Y.G. Body contouring by lipolysis: A five-year experience with over 3000 cases. *Plast. Reconstr. Surg.* **1983**, *72*, 591–597. [\[CrossRef\]](#)
34. Illouz, Y.G. De l’utilization de la graisse aspiree pour combler les defects cutanes observations. *Aesthetic Plast. Surg. Rev. Chir. Esthet. Lang. Fr.* **1985**, *10*, 13–20.
35. Wetmore, S.J. Injection of Fat for Soft Tissue Augmentation. *Laryngoscope* **1989**, *99*, 50–57. [\[CrossRef\]](#)
36. Teimourian, B. Blindness following fat injections [letter]. *Plast. Reconstr. Surg.* **1988**, *82*, 361. [\[CrossRef\]](#)
37. Illouz, Y.G. Present results of fat injection. *Aesthetic Plast. Surg.* **1988**, *12*, 175–181. [\[CrossRef\]](#)
38. Chia, C.T.; Neinstein, R.M.; Theodorou, S.J. Evidence-Based Medicine: Liposuction. *Plast. Reconstr. Surg.* **2017**, *139*, 267e–274e. [\[CrossRef\]](#)
39. Agris, J. Autologous fat transplantation: A 3-year study [abstract]. *Am. J. Cosmet. Surg.* **1987**, *4*, 111. [\[CrossRef\]](#)
40. Šmahel, J. Adipose Tissue in Plastic Surgery. *Ann. Plast. Surg.* **1986**, *16*, 444–453. [\[CrossRef\]](#) [\[PubMed\]](#)
41. Zocchi, M. Methode de production de collagene autologue par traitement du tissu graisseux. *J. Med. Esthet. Chirur. Dermatol.* **1990**, *66*, 105–114.
42. Klein, J.A. The Tumescence Technique for Lipo-Suction Surgery. *Am. J. Cosmet. Surg.* **1987**, *4*, 263–267. [\[CrossRef\]](#)
43. Billings, E., Jr.; May, J.W., Jr. Historical review and present status of free graft and autotransplantation in plastic and reconstructive surgery. *Plast. Reconstr. Surg.* **1989**, *83*, 368–381. [\[CrossRef\]](#) [\[PubMed\]](#)

44. Roenigk, H., Jr.; Rubenstein, R. Combined scalp reduction and autologous fat implant treatment of localized soft tissue defects. *J. Dermatol. Surg. Oncol.* **1988**, *14*, 67–70. [[CrossRef](#)] [[PubMed](#)]
45. Moscona, R.; Ullman, Y.; Har-Shai, Y.; Hirshowitz, B. Free-fat injections for the correction of hemifacial atrophy. *Plast. Reconstr. Surg.* **1989**, *84*, 501–507. [[CrossRef](#)] [[PubMed](#)]
46. Tonnard, P.; Verpaele, A.; Carvas, M. Fat Grafting for Facial Rejuvenation with Nanofat Grafts. *Clin. Plast. Surg.* **2019**, *47*, 53–62. [[CrossRef](#)]
47. Shukla, L.; Yuan, Y.; Shayan, R.; Greening, D.; Karnezis, T. Fat Therapeutics: The Clinical Capacity of Adipose-Derived Stem Cells and Exosomes for Human Disease and Tissue Regeneration. *Front. Pharmacol.* **2020**, *11*, 158. [[CrossRef](#)]
48. Bora, P.; Majumdar, A.S. Adipose tissue-derived stromal vascular fraction in regenerative medicine: A brief review on biology and translation. *Stem Cell Res. Ther.* **2017**, *8*, 158. [[CrossRef](#)]
49. Jatana, K.R.; Smith, S.P., Jr. The scientific basis for lipotransfer: Is it the ideal filler? *Facial Plast. Surg. Clin. N. Am.* **2008**, *16*, 443–448. [[CrossRef](#)]
50. Coleman, S.R. Structural fat grafting: More than a permanent filler. *Plast. Reconstr. Surg.* **2006**, *118*, 108S–120S. [[CrossRef](#)]
51. Del Vecchio, D.; Wall, S., Jr. Expansion Vibration Lipofilling: A New Technique in Large-Volume Fat Transplantation. *Plast. Reconstr. Surg.* **2018**, *141*, 639e–649e. [[CrossRef](#)] [[PubMed](#)]
52. Simonacci, F.; Bertozzi, N.; Grieco, M.P.; Grignaffini, E.; Raposio, E. Procedure, applications, and outcomes of autologous fat grafting. *Ann. Med. Surg.* **2017**, *27*, 49–60. [[CrossRef](#)]
53. Gause, T.M., 2nd; Kling, R.E.; Sivak, W.N.; Marra, K.G.; Rubin, J.P.; Kokai, L.E. Particle size in fat graft retention: A review on the impact of harvesting technique in lipofilling surgical outcomes. *Adipocyte* **2014**, *3*, 273–279. [[CrossRef](#)]
54. Gentile, P.; De Angelis, B.; Di Pietro, V.; Amorosi, V.; Scioli, M.G.; Orlandi, A.; Cervelli, V. Gentle is better: The original “gentle technique” for fat placement in breast lipofilling. *J. Cutan. Aesthetic Surg.* **2018**, *11*, 120–126. [[CrossRef](#)] [[PubMed](#)]
55. Peer, L.A. Loss of weight and volume in human fat grafts: With postulation of a “cell survival theory”. *Plast. Reconstr. Surg.* **1950**, *5*, 217–230. [[CrossRef](#)]
56. Nguyen, A.; Pasyk, K.A.; Bouvier, T.N.; Hassett, C.A.; Argenta, L.C. Comparative study of survival of autologous adipose tissue taken and transplanted by different techniques. *Plast. Reconstr. Surg.* **1990**, *85*, 378–386. [[CrossRef](#)]
57. Epply, B.A.; Sidner, R.A.; Platis, J.M. Bioactivation of free-fat transfers: A potential new approach to improving graft survival. *Plast. Reconstr. Surg.* **1992**, *90*, 1021–1030. [[CrossRef](#)]
58. Saunders, M.C.; Keller, J.T.; Dunsker, S.B.; Mayfield, F.H. Survival of Autologous Fat Grafts in Humans and in Mice. *Connect. Tissue Res.* **1981**, *8*, 85–91. [[CrossRef](#)]
59. Gurney, C.E. Experimental study of the behavior of free fat transplants. *Surgery* **1938**, *3*, 680.
60. Johnson, G.W. Body Contouring by Macroinjection of Autogenous Fat. *Am. J. Cosmet. Surg.* **1987**, *4*, 103–109. [[CrossRef](#)]
61. Gormley, D.E.; Eremia, S. Quantitative Assessment of Augmentation Therapy. *J. Dermatol. Surg. Oncol.* **1990**, *16*, 1147–1151. [[CrossRef](#)]
62. Hörl, H.W.; Feller, A.-M.; Biemer, E. Technique for Liposuction Fat Reimplantation and Long-Term Volume Evaluation by Magnetic Resonance Imaging. *Ann. Plast. Surg.* **1991**, *26*, 248–258. [[CrossRef](#)]
63. Rigotti, G.; Marchi, A.; Micciolo, R.; Baroni, G. Autologous fat grafting in breast cancer patients. *Breast* **2012**, *21*, 690. [[CrossRef](#)]
64. Zarei, F.; Abbaszadeh, A. Application of Cell Therapy for Anti-Aging Facial Skin. *Curr. Stem. Cell Res. Ther.* **2019**, *14*, 244–248. [[CrossRef](#)]
65. Naderi, N.; Combella, E.J.; Griffin, M.; Sedaghati, T.; Javed, M.; Findlay, M.W.; Wallace, C.G.; Mosahebi, A.; Butler, P.E.; Seifalian, A.M.; et al. The regenerative role of adipose-derived stem cells (ADSC) in plastic and reconstructive surgery. *Int. Wound J.* **2016**, *14*, 112–124. [[CrossRef](#)] [[PubMed](#)]
66. Won, C.H.; Park, G.-H.; Wu, X.; Tran, T.-N.; Park, K.-Y.; Park, B.-S.; Kim, D.Y.; Kwon, O.; Kim, K.-H. The Basic Mechanism of Hair Growth Stimulation by Adipose-derived Stem Cells and Their Secretory Factors. *Curr. Stem Cell Res. Ther.* **2017**, *12*, 535–543. [[CrossRef](#)] [[PubMed](#)]
67. Addeman, B.T.; Kutty, S.; Perkins, T.G.; Soliman, A.S.; Wiens, C.N.; McCurdy, C.M.; Beaton, M.D.; Hegele, R.A.; McKenzie, C.A. Validation of volumetric and single-slice MRI adipose analysis using a novel fully automated segmentation method. *J. Magn. Reson. Imaging* **2014**, *41*, 233–241. [[CrossRef](#)] [[PubMed](#)]
68. Glogau, R.G. Microlipoinjection. *Arch. Dermatol.* **1988**, *124*, 1340–1343. [[CrossRef](#)] [[PubMed](#)]
69. Haiavy, J.; Elias, H. Injectable Fillers in the Upper Face. *Atlas. Oral Maxillofac. Surg. Clin. N. Am.* **2016**, *24*, 105–116. [[CrossRef](#)]
70. Pu, L.L. Mechanisms of Fat Graft Survival. *Ann. Plast. Surg.* **2016**, *77*, S84–S86. [[CrossRef](#)] [[PubMed](#)]
71. Truswell, W. Aging Changes of the Periorbital, Cheeks, and Midface. *Facial Plast. Surg.* **2013**, *29*, 3–12. [[CrossRef](#)]
72. Herold, C.; Ueberreiter, K.; Busche, M.N.; Vogt, P.M. Autologous Fat Transplantation: Volumetric Tools for Estimation of Volume Survival. A Systematic Review. *Aesthetic Plast. Surg.* **2013**, *37*, 380–387. [[CrossRef](#)]
73. Kaufman, M.R.; Bradley, J.P.; Dickinson, B.; Heller, J.B.; Wasson, K.; O'Hara, C.; Huang, C.; Gabbay, J.; Ghadjar, K.; Miller, T.A. Autologous Fat Transfer National Consensus Survey: Trends in Techniques for Harvest, Preparation, and Application, and Perception of Short- and Long-Term Results. *Plast. Reconstr. Surg.* **2007**, *119*, 323–331. [[CrossRef](#)]
74. Li, Y.; Mou, S.; Xiao, P.; Li, G.; Li, J.; Tong, J.; Wang, J.; Yang, J.; Sun, J.; Wang, Z. Delayed two steps PRP injection strategy for the improvement of fat graft survival with superior angiogenesis. *Sci. Rep.* **2020**, *10*, 5231–5238. [[CrossRef](#)]
75. Modarressi, A. Platelet Rich Plasma (PRP) Improves Fat Grafting Outcomes. *World J. Plast. Surg.* **2013**, *2*, 6–13.

76. Kanchwala, S.K.; Holloway, L.; Bucky, L.P. Reliable soft tissue augmentation: A clinical comparison of injectable soft-tissue fillers for facial-volume augmentation. *Ann. Plast. Surg.* **2005**, *55*, 30–35. [[CrossRef](#)] [[PubMed](#)]
77. Maamari, R.N.; Massry, G.G.; Holds, J.B. Complications Associated with Fat Grafting to the Lower Eyelid. *Facial Plast. Surg. Clin. N. Am.* **2019**, *27*, 435–441. [[CrossRef](#)] [[PubMed](#)]
78. Cuzalina, A.; Guerrero, A.V. Complications in Fat Grafting. *Atlas. Oral Maxillofac. Surg. Clin. N. Am.* **2018**, *26*, 77–80. [[CrossRef](#)] [[PubMed](#)]
79. Belyea, J.; Hart, R.; Trites, J.; Taylor, S.M. A case of autologous microfat grafting in lip reconstruction of a whistle deformity following cancer treatment. *Can. J. Plast. Surg.* **2010**, *18*, e53–e54. [[CrossRef](#)] [[PubMed](#)]
80. Ueland, H.O.; Nilsen, R.M.; Rødahl, E.; Jensen, S.A. Hyaluronic acid is superior to autologous fat for treatment of temporal hollowing after lateral orbital wall decompression: A prospective interventional trial. *J. Plast. Reconstr. Aesthetic Surg.* **2019**, *72*, 973–981. [[CrossRef](#)] [[PubMed](#)]
81. Shuck, J.; Iorio, M.L.; Hung, R.; Davison, S.P. Autologous fat grafting and injectable dermal fillers for human immunodeficiency virus-associated facial lipodystrophy: A comparison of safety, efficacy, and long-term treatment outcomes. *Plast. Reconstr. Surg.* **2013**, *131*, 499–506. [[CrossRef](#)]
82. Rohrich, R.J.; Pessa, J.E.; Ristow, B. The Youthful Cheek and the Deep Medial Fat Compartment. *Plast. Reconstr. Surg.* **2008**, *121*, 2107–2112. [[CrossRef](#)]
83. Wang, F.; Garza, L.A.; Kang, S.; Varani, J.; Orringer, J.S.; Fisher, G.J.; Voorhees, J.J. In Vivo stimulation of de novo collagen production caused by cross-linked hyaluronic acid dermal filler injections in photo-damaged human skin. *Arch. Dermatol.* **2007**, *143*, 155–163. [[CrossRef](#)]
84. Zerbinati, N.; Sommatitis, S.; Maccario, C.; Capillo, M.; Grimaldi, G.; Alonci, G.; Protasoni, M.; Rauso, R.; Mocchi, R. Toward Physicochemical and Rheological Characterization of Different Injectable Hyaluronic Acid Dermal Fillers Cross-Linked with Polyethylene Glycol Diglycidyl Ether. *Polymers* **2021**, *13*, 948. [[CrossRef](#)]
85. Zerbinati, N.; Esposito, C.; Cipolla, G.; Calligaro, A.; Monticelli, D.; Martina, V.; Golubovic, M.; Binic, I.; Sigova, J.; Gallo, A.L.; et al. Chemical and mechanical characterization of hyaluronic acid hydrogel cross-linked with polyethylen glycol and its use in dermatology. *Dermatol. Ther.* **2020**, *33*, e13747. [[CrossRef](#)] [[PubMed](#)]
86. Monticelli, D.; Martina, V.; Mocchi, R.; Rauso, R.; Zerbinati, U.; Cipolla, G.; Zerbinati, N. Chemical Characterization of Hydrogels Crosslinked with Polyethylene Glycol for Soft Tissue Augmentation. *Open Access Maced. J. Med. Sci.* **2019**, *7*, 1077–1081. [[CrossRef](#)] [[PubMed](#)]
87. Marino, F.; Cosentino, M.; Legnaro, M.; Luini, A.; Sigova, J.; Mocchi, R.; Lotti, T.; Zerbinati, N.; Gasperina, D.; Tirant, M.; et al. Immune profile of hyaluronic acid hydrogel polyethylene glycol crosslinked: An in vitro evaluation in human polymorphonuclear leukocytes. *Dermatol. Ther.* **2020**, *33*, e13388. [[CrossRef](#)]
88. Zerbinati, N.; D'Este, E.; Farina, A.; Rauso, R.; Cherubino, M.; Calligaro, A. Morphological evidences following pegylated filler treatment in human skin. *J. Biol. Regul. Homeost. Agents* **2017**, *31*, 79–85.
89. Zerbinati, N.; Lotti, T.; Monticelli, D.; Martina, V.; Cipolla, G.; D'Este, E.; Calligaro, A.; Mocchi, R.; Maccario, C.; Sommatitis, S.; et al. In Vitro Evaluation of the Sensitivity of a Hyaluronic Acid PEG Cross-Linked to Bovine Testes Hyaluronidase. *Open Access Maced. J. Med. Sci.* **2018**, *6*, 20–24. [[CrossRef](#)] [[PubMed](#)]
90. Rauso, R.; Bove, P.; Rugge, L.; Chirico, F. Unusual Intraoral Necrosis After Hyaluronic Acid Injections. *Dermatol. Surg.* **2021**, *47*, 1158–1160. [[CrossRef](#)]
91. Rauso, R.; Zerbinati, N.; Franco, R.; Chirico, F.; Ronchi, A.; Sesenna, E.; Colella, G.; Tartaro, G. Cross-linked hyaluronic acid filler hydrolysis with hyaluronidase: Different settings to reproduce different clinical scenarios. *Dermatol. Ther.* **2020**, *33*, e13269. [[CrossRef](#)]
92. Rauso, R.; Colella, G.; Franco, R.; Chirico, F.; Ronchi, A.; Federico, F.; Volpicelli, A.; Tartaro, G. Is hyaluronidase able to reverse embolism associated with hyaluronic acid filler? An anatomical case study. *J. Biol. Regul. Homeost. Agents* **2020**, *33*, 1927–1930.
93. Rauso, R.; Sesenna, E.; Fragola, R.; Zerbinati, N.; Nicoletti, G.F.; Tartaro, G. Skin Necrosis and Vision Loss or Impairment After Facial Filler Injection. *J. Craniofac. Surg.* **2020**, *31*, 2289–2293. [[CrossRef](#)]
94. Zerbinati, N.; Mocchi, R.; Galadari, H.; Maccario, C.; Maggi, M.; Rauso, R.; Passi, A.; Esposito, C.; Sommatitis, S. In Vitro Evaluation of the Biological Availability of Hyaluronic Acid Polyethylene Glycols-Cross-Linked Hydrogels to Bovine Testes Hyaluronidase. *BioMed Res. Int.* **2019**. [[CrossRef](#)]
95. Zerbinati, N.; Lotti, T.; Monticelli, D.; Rauso, R.; González-Isaza, P.; D'Este, E.; Calligaro, A.; Sommatitis, S.; Maccario, C.; Mocchi, R.; et al. In Vitro Evaluation of the Biosafety of Hyaluronic Acid PEG Cross-Linked with Micromolecules of Calcium Hydroxyapatite in Low Concentration. *Open Access Maced. J. Med. Sci.* **2018**, *6*, 15–19. [[CrossRef](#)]
96. Artzi, O.; Loizides, C.; Verner, I.; Landau, M. Resistant and Recurrent Late Reaction to Hyaluronic Acid-Based Gel. *Dermatol. Surg.* **2016**, *42*, 31–37. [[CrossRef](#)] [[PubMed](#)]
97. Friedman, P.M.; Mafong, E.A.; Kauvar, A.N.; Geronemus, R.G. Safety data of injectable nonanimal stabilized hyaluronic acid gel for soft tissue augmentation. *Dermatol. Surg.* **2002**, *28*, 491–494. [[PubMed](#)]
98. Becker, L.C.; Bergfeld, W.F.; Belsito, D.V.; Klaassen, C.D.; Marks, J.G.; Shank, R.C.; Slaga, T.J.; Snyder, P.W.; Panel, W.C.I.R.E.; Andersen, F.A. Final Report of the Safety Assessment of Hyaluronic Acid, Potassium Hyaluronate, and Sodium Hyaluronate. *Int. J. Toxicol.* **2009**, *28*, 5–67. [[CrossRef](#)] [[PubMed](#)]

99. Salti, G.; Fundarò, S.P. Evaluation of the Rheologic and Physicochemical Properties of a Novel Hyaluronic Acid Filler Range with eXcellent Three-Dimensional Reticulation (XTR™) Technology. *Polymers* **2020**, *12*, 1644. [\[CrossRef\]](#)
100. Fallacara, A.; Durini, E.; Vertuani, S.; Manfredini, S. Hyaluronic Acid Fillers in Soft Tissue Regeneration. *Facial Plast. Surg.* **2017**, *33*, 087–096. [\[CrossRef\]](#) [\[PubMed\]](#)
101. Mashiko, T.; Mori, H.; Kato, H.; Doi, K.; Kuno, S.; Kinoshita, K.; Kunimatsu, A.; Ohtomo, K.; Yoshimura, K. Semipermanent volumization by an absorbable filler: Onlay injection technique to the bone. *Plast. Reconstr. Surg. Glob. Open* **2013**, *1*, e4–e14. [\[CrossRef\]](#)
102. Eccleston, D.; Murphy, D.K. Juvederm VOLBELLA in the peri-oral area: A 12 month prospective, multicenter, open label study. *Clin. Cosmet. Investig. Dermatol.* **2012**, *5*, 1–6.
103. Pierre, S.; Liew, S.; Bernardin, A. Basics of dermal filler rheology. *Dermatol. Surg.* **2015**, *41*, S120–S126. [\[CrossRef\]](#)
104. Salti, G.; Rauso, R. Facial rejuvenation with fillers: The dual plane technique. *J. Cutan. Aesthetic Surg.* **2015**, *8*, 127–133. [\[CrossRef\]](#) [\[PubMed\]](#)
105. Hee, C.K.; Shumate, G.T.; Narurkar, V.; Bernardin, A.; Messina, D.J. Rheological Properties and In Vivo Performance Characteristics of Soft Tissue Fillers. *Dermatol. Surg.* **2015**, *41*, S373–S381. [\[CrossRef\]](#) [\[PubMed\]](#)
106. Rauso, R.; Federico, F.; Zerbinati, N.; De Cicco, D.; Nicoletti, G.F.; Tartaro, G. Hyaluronic Acid Injections to Correct Lips Deformity Following Surgical Removal of Permanent Implant. *J. Craniofac. Surg.* **2020**, *31*, e604–e606. [\[CrossRef\]](#) [\[PubMed\]](#)
107. Rauso, R.; Califano, L.; Rugge, L.; Chirico, F.; Tartaro, G. Surgical Lip Remodeling After Injection of Permanent Filler. *Aesthetic Surg. J.* **2018**, *39*, 565–571. [\[CrossRef\]](#)
108. Schweiger, E.S.; Riddle, C.C.; Tonkovic-Capin, V.; Aires, D.J. Successful treatment with injected hyaluronic acid in a patient with lip asymmetry after surgical correction of cleft lip. *Dermatol. Surg.* **2008**, *34*, 717–719. [\[PubMed\]](#)
109. Stolic, D.; Jankovic, M.; Draskovic, M.; Georgiev, S.; Stolic, M. The Surgical Lips Deformity Corrected with Hyaluronic Fillers: A Case Report. *Open Access Maced. J. Med. Sci.* **2015**, *3*, 423–425. [\[CrossRef\]](#)
110. Rahman, E.; Kandhari, R.; Goodman, G.J.; Signorini, M. Use of a hyaluronic acid soft-tissue filler to correct congenital and post-traumatic lip asymmetry. *J. Cutan. Aesthetic Surg.* **2017**, *10*, 153–156. [\[CrossRef\]](#)
111. Rauso, R.; Colella, G.; Franco, R.; Ronchi, A.; Chirico, F. Ossified Carcinoma Ex Pleomorphic Adenoma in accessory lobe of parotid gland: Complexity in clinical, imaging and histologic diagnosis and minimally invasive surgery. *Oral Oncol.* **2019**, *92*, 95–98. [\[CrossRef\]](#)
112. Tamplen, M.; Knott, P.D.; Fritz, M.A.; Seth, R. Controversies in Parotid Defect Reconstruction. *Facial Plast. Surg. Clin. N. Am.* **2016**, *24*, 235–243. [\[CrossRef\]](#)
113. Cannady, S.B.; Seth, R.; Fritz, M.A.; Alam, D.S.; Wax, M.K. Total parotidectomy defect reconstruction using the buried free flap. *Otolaryngol. Head Neck Surg.* **2010**, *143*, 637–643. [\[CrossRef\]](#) [\[PubMed\]](#)
114. Clauser, L.; Polito, J.; Mandrioli, S.; Tieghi, R.; Denes, S.A.; Galiè, M. Structural Fat Grafting in Complex Reconstructive Surgery. *J. Craniofac. Surg.* **2008**, *19*, 187–191. [\[CrossRef\]](#) [\[PubMed\]](#)
115. Curry, J.M.; Fisher, K.W.; Heffelfinger, R.N.; Rosen, M.R.; Keane, W.M.; Pribitkin, E.A. Superficial Musculoaponeurotic System Elevation and Fat Graft Reconstruction After Superficial Parotidectomy. *Laryngoscope* **2008**, *118*, 210–215. [\[CrossRef\]](#) [\[PubMed\]](#)
116. Natghian, H.; Song, M.; Jayamohan, J.; Johnson, D.; Magdum, S.; Richards, P.; Wall, S. Long-Term Results in Isolated Metopic Synostosis: The Oxford Experience over 22 Years. *Plast. Reconstr. Surg.* **2018**, *142*, 509e–515e. [\[CrossRef\]](#) [\[PubMed\]](#)
117. Cohen, S.R.; Kawamoto, H.K., Jr.; Burstein, F.; Peacock, W.J. Advancement-onlay: An improved technique of fronto-orbital remodeling in craniosynostosis. *Childs Nerv. Syst.* **1991**, *7*, 264–271. [\[CrossRef\]](#) [\[PubMed\]](#)
118. Deyerle, W.M.; Crossland, S.; Sullivan, H. Methylmethacrylate: Uses and complications. *AORN J.* **1979**, *29*, 696–712. [\[CrossRef\]](#)
119. Shapiro, S.A. Cranioplasty, Vertebral Body Replacement, and Spinal Fusion with Tobramycin-impregnated Methylmethacrylate. *Neurosurgery* **1991**, *28*, 789–791. [\[CrossRef\]](#)
120. Blum, K.S.; Schneider, S.J.; Rosenthal, A.D. Methylmethacrylate cranioplasty in children: Long-term results. *Pediatr. Neurosurg.* **1997**, *26*, 33–35. [\[CrossRef\]](#)
121. Replogle, R.E.; Lanzino, G.; Francel, P.; Henson, S.; Lin, K.; Jane, J.A. Acrylic Cranioplasty Using Miniplate Struts. *Neurosurgery* **1996**, *39*, 747–749. [\[CrossRef\]](#) [\[PubMed\]](#)
122. Constantino, P.D.; Friedman, C.D.; Jones, K.; Chow, L.C.; Pelzer, H.J.; Sisson, G.A., Sr. Hydroxyapatite cement. I. Basic chemistry and histologic properties. *Arch. Otolaryngol. Head Neck Surg.* **1991**, *117*, 379–384. [\[CrossRef\]](#) [\[PubMed\]](#)
123. Friedman, C.D.; Costantino, P.D.; Takagi, S.; Chow, L.C. BoneSource? hydroxyapatite cement: A novel biomaterial for craniofacial skeletal tissue engineering and reconstruction. *J. Biomed. Mater. Res.* **1998**, *43*, 428–432. [\[CrossRef\]](#)
124. Al-Nuaimi, Y.; Sherratt, M.J.; Griffiths, C.E.M. Skin health in older age. *Maturitas* **2014**, *79*, 256–264. [\[CrossRef\]](#)
125. Greco, R.M.; Iocono, J.A.; Ehrlich, H.P. Hyaluronic acid stimulates human fibroblast proliferation within a collagen matrix. *J. Cell. Physiol.* **1998**, *177*, 465–473. [\[CrossRef\]](#)
126. Mast, B.A.; Diegelmann, R.F.; Krummel, T.M.; Cohen, I.K. Hyaluronic Acid Modulates Proliferation, Collagen and Protein Synthesis of Cultured Fetal Fibroblasts. *Matrix* **1993**, *13*, 441–446. [\[CrossRef\]](#)
127. Croce, M.; Dyne, K.; Boraldi, F.; Quagliano, D.; Cetta, G.; Tiozzo, R.; Ronchetti, I.P. Hyaluronan affects protein and collagen synthesis by in vitro human skin fibroblasts. *Tissue Cell* **2001**, *33*, 326–331. [\[CrossRef\]](#)
128. Huang-Lee, L.L.; Nimni, M.E. Fibroblast contraction of collagen matrices with and without covalently bound hyaluronan. *J. Biomater. Sci. Polym. Ed.* **1994**, *5*, 99–109. [\[CrossRef\]](#)

129. Iocono, J.A.; Krummel, T.M.; Keefer, K.A.; Allison, G.M.; Paul Ehrlich, H. Repeated additions of hyaluronan alters granulation tissue deposition in sponge implants in mice. *Wound Repair Regen.* **1998**, *6*, 442–448. [[CrossRef](#)] [[PubMed](#)]
130. Paliwal, S.; Fagien, S.; Sun, X.; Holt, T.; Kim, T.; Hee, C.K.; Van Epps, D.; Messina, D.J. Skin extracellular matrix stimulation following injection of a hyaluronic acid-based dermal filler in a rat model. *Plast. Reconstr. Surg.* **2014**, *134*, 1224–1233. [[CrossRef](#)]
131. Quan, T.; Wang, F.; Shao, Y.; Rittié, L.; Xia, W.; Orringer, J.S.; Voorhees, J.J.; Fisher, G.J. Enhancing Structural Support of the Dermal Microenvironment Activates Fibroblasts, Endothelial Cells, and Keratinocytes in Aged Human Skin In Vivo. *J. Investig. Dermatol.* **2013**, *133*, 658–667. [[CrossRef](#)]
132. Zerbinati, N.; D'Este, E.; Parodi, P.C.; Calligaro, A. Microscopic and ultrastructural evidences in human skin following calcium hydroxylapatite filler treatment. *Arch. Dermatol. Res.* **2017**, *309*, 389–396. [[CrossRef](#)] [[PubMed](#)]
133. Maytin, E.V. Hyaluronan: More than just a wrinkle filler. *Glycobiology* **2016**, *26*, 553–559. [[CrossRef](#)] [[PubMed](#)]
134. Rauso, R.; Nicoletti, G.F.; Sesenna, E.; Faro, C.L.; Chirico, F.; Fragola, R.; Giudice, G.L.; Tartaro, G. Superficial Temporal Artery Perforator Flap: Indications, Surgical Outcomes, and Donor Site Morbidity. *Dent. J.* **2020**, *8*, 117. [[CrossRef](#)] [[PubMed](#)]
135. Ohlsén, L.; Skoog, T.; Sohn, S.A. The pathogenesis of cauliflower ear. An experimental study in rabbits. *Scand. J. Plast. Reconstr. Surg.* **1975**, *9*, 34–39. [[CrossRef](#)]
136. Benecke, J.E., Jr.; Gadre, A.K.; Linthicum, F.H., Jr. Chondrogenic potential of tragal perichondrium: A cause of hearing loss following stapedectomy. *Laryngoscope* **1990**, *100*, 1292–1293. [[CrossRef](#)]
137. Abrahamsson, P.; Isaksson, S.; Gordh, M.; Andersson, G. Periosteal expansion of rabbit mandible with an osmotic self-inflatable expander. *Scand. J. Plast. Reconstr. Surg. Hand Surg.* **2009**, *43*, 121–125. [[CrossRef](#)]
138. Sgaramella, N.; Wilms, T.; Boldrup, L.; Loljung, L.; Gu, X.; Coates, P.; Califano, L.; Muzio, L.L.; Spaak, L.N.; Franco, R.; et al. Ethnicity based variation in expression of E-cadherin in patients with squamous cell carcinoma of the oral tongue. *Oncol. Lett.* **2018**, *16*, 6603–6607. [[CrossRef](#)]
139. Hanasono, M.M.; Silva, A.; Yu, P.; Skoracki, R.J. A Comprehensive Algorithm for Oncologic Maxillary Reconstruction. *Plast. Reconstr. Surg.* **2013**, *131*, 47–60. [[CrossRef](#)]
140. Rauso, R.; Colella, G.; Chirico, F.; Fragola, R.; Nicoletti, G.F.; Faro, C.L.; Tartaro, G. Alar facial sulcus and nasal ala reconstruction: A challenging anatomical area. *Minerva Dent. Oral Sci.* **2021**, *70*, 130–132. [[CrossRef](#)] [[PubMed](#)]
141. Cordeiro, P.G.; Santamaria, E. A Classification System and Algorithm for Reconstruction of Maxillectomy and Midfacial Defects. *Plast. Reconstr. Surg.* **2000**, *105*, 2331–2346. [[CrossRef](#)] [[PubMed](#)]
142. Pipkorn, P.; Rosenquist, K.; Zenga, J. Functional considerations in oral cavity reconstruction. *Curr. Opin. Otolaryngol. Head Neck Surg.* **2018**, *26*, 326–333. [[CrossRef](#)] [[PubMed](#)]
143. Jaquet, Y.; Enepekides, D.J.; Torgerson, C.; Higgins, K.M. Radial Forearm Free Flap Donor Site Morbidity Ulnar-Based Transposition Flap vs Split-Thickness Skin Graft. *Arch. Otolaryngol. Head Neck Surg.* **2012**, *138*, 38–43. [[CrossRef](#)] [[PubMed](#)]
144. Rauso, R.; Colella, G.; Rugge, L.; Chirico, F.; Tartaro, G. Alternative suture technique for anastomosis of veins with different diameters. *Br. J. Oral Maxillofac. Surg.* **2019**, *57*, 682–684. [[CrossRef](#)] [[PubMed](#)]
145. Rauso, R.; Chirico, F.; Federico, F.; Nicoletti, G.F.; Colella, G.; Fragola, R.; Pafundi, P.C.; Tartaro, G. Maxillo-facial reconstruction following cancer ablation during COVID-19 pandemic in southern Italy. *Oral Oncol.* **2020**, *115*, 105114. [[CrossRef](#)] [[PubMed](#)]
146. Massarelli, O.; Vaira, L.; Gobbi, R.; Biglio, A.; Orabona, G.D.; De Riu, G. Soft palate functional reconstruction with buccinator myomucosal island flaps. *Int. J. Oral Maxillofac. Surg.* **2018**, *47*, 316–323. [[CrossRef](#)]