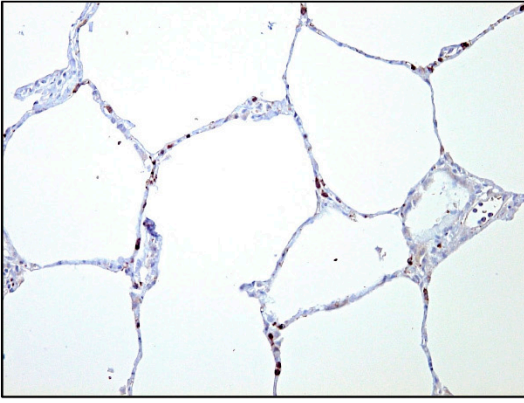
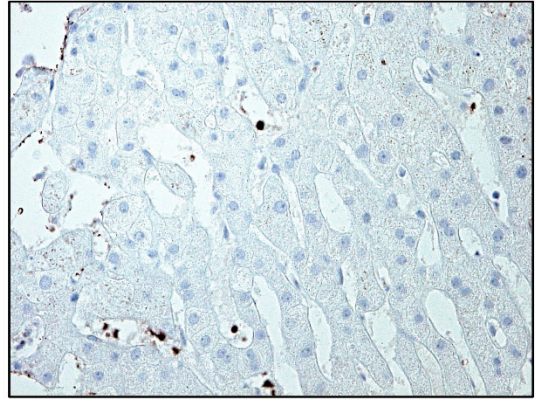


A**B**

Supplementary Figure 1 Healthy control biopsy

- A) Immunohistochemical staining of IL-6 in a healthy lung biopsy (20x magnification).
- B) Immunohistochemical staining of IL-6 in healthy liver biopsy (40x magnification) showing sparse IL-6-producing cells within capillaries of liver lobules.