



Article

A One-Year, Multicenter, Retrospective Evaluation of Narrow and Low-Profile Abutments Used to Rehabilitate Complete Edentulous Lower Arches: The OT Bridge Concept

Marco Montanari ¹, Roberto Scrasecia ², Gabriele Cervino ^{3,*} , Massimo Pasi ⁴, Emiliano Ferrari ⁵, Ertaxhanari ⁶, Alba Koshovari ⁶ and Marco Tallarico ⁷

¹ Private Practice, 41121 Cesena, Italy; docmontanari.marco@gmail.com

² Private Practice, 74121 Taranto, Italy; roberto.scrascia@gmail.com

³ Department of Biomedical and Dental Sciences, Morphological and Functional Images, University of Messina, Policlinico G. Martino, Via Consolare Valeria, 98100 Messina, Italy

⁴ Dental Department, CLMOPD Ateneo Vita-Salute San Raffaele, 20100 Milan, Italy; mpasi@massimopasi.it

⁵ Private Practice, 40123 Bologna, Italy; emo72@tiscali.it

⁶ Department of Implantology and Prosthetic Aspects, Master of Science in Dentistry Program, Aldent University, 1022 Tirana, Albania; info@ertaxhanari.com (E.X.); alba.koshovari@ual.edu.al (A.K.)

⁷ Department of Medical, Surgical and Experimental Sciences, University of Sassari, 07100 Sassari, Italy; me@studiomarcotallarico.it

* Correspondence: gcervino@unime.it

Received: 26 October 2020; Accepted: 24 November 2020; Published: 1 December 2020



Abstract: Purpose: To evaluate preliminary data on survival and success rates of immediately loaded, screw-retained, restorations delivered on lower arches using narrow and low-profile OT Equator abutments. Methods: This retrospective study analyzed data of patients rehabilitated with OT Bridge (fixed prosthetic system built on OT Equator) prosthetic concept from November 2017 to February 2019 in five different centers. Outcome measures were implant and prosthetic survival rates, biological and technical complications, marginal bone loss (MBL), oral health impact profile (OHIP), bleeding on probing, and plaque index. Results: A total of 60 implants were inserted in 12 patients. Patients were followed for a mean period of 15.8 months (range 12–24). All the patients received OT Equator as intermediate abutments. Four out of 60 implants were connected to the prosthetic framework using only the Seeger system, without a screw. One year after loading, three implants failed (implant survival rate of 95.0%) in two patients. No prosthesis failed and no major biological and technical complications were experienced. One year after initial loading, the marginal bone level was 0.32 ± 0.2 mm. The OHIP before treatment was 87.7 ± 6.0 . One year after treatment, OHIP was 23.6 ± 1.2 . The difference was statistically significant (64.1 ± 7.2 ; $p = 0.0000$). One year after loading, 8.9% of the examined implant sites present positive bleeding on probing, while 5.8% of the implant sites presented plaque. Conclusions: The OT Equator abutments showed successful results when used to support mandible fixed dental prosthesis delivered on 4–6 implants. Whole prosthetic survival and success rates, high patient satisfaction, and good biological parameters were experienced one year after function. Further prospective studies are needed to confirm these preliminary results.

Keywords: complete edentulous; OT Bridge; immediate loading; lower arch; dental implants

1. Introduction

In elderly people, one of the most important problems in dental healthcare is edentulism. Complete removable dentures were the conventional solution for treating edentulism; nevertheless,

the expectations of the elderly population have changed in the last years with the desire for more stable prosthesis using dental implants. A reliable compromise in the lower arch is a tissue-supported and implant-retained overdenture delivered on two implants [1]. Among the benefits of this prosthetic solution, a conventional implant-supported overdenture is an economically viable solution, and easy for the patients to keep clean and maintain. In the literature, several studies supported the ease of keeping overdenture clean [1]. On the other hand, in patients with good hygienic maintenance, suitable hard and soft tissues conditions, and dealing with more complex surgical and prosthetic procedures, insertion of a higher number of implants enables the delivery of a fixed or hybrid implant-supported prosthesis [2]. Although the debate on the most appropriate implant number and position is still ongoing, six implants may be preferable to four in the longer follow-up, reducing the amount of peri-implant bone loss [3] when a fixed solution is proposed. In fact, hygienic maintenance of the prosthesis can be challenging, particularly in patients classified as Cawood and Howell class V or VI, when extensive prosthetic flanges are needed. In these patients, a hybrid overdenture (implant-supported) can be a reliable option. As the name implies, hybrid overdenture consists of a metal bar permanently fixed on implants to support an overdenture (metal counterpart and acrylic teeth). This solution allows a fixed solution that can be removed by the patient.

Immediate or delayed loading protocol were used according to well established criteria, including primary implant stability. Following this protocol, patients may receive definitive abutment screwed on implants at the time of surgery. Nevertheless, this could affect the amount of bone loss [4]. Different implant abutment types could be selected to deliver a temporary or definitive implant-supported restoration. Although there are still no clear benefits between cemented- or screw-retained restorations, in 2018, Tallarico et al. [5] conducted a consensus conference on prosthetic aspect, showing that a screw-retained restoration should be suggested because it is easier to remove and repair. However, the main concern regarding an implant-supported, screw-retained restoration was that the implants must be placed as parallel as possible. Nevertheless, today, it is not easier to evaluate the maximum degree of accepted disparallelism among implants. The overall number of placed implants and their tridimensional position makes it difficult to get. Computer-assisted, template-based surgery may help to insert parallel implants, even if errors in angle may occur [6–10]. Moreover, tilted implants could be planned according to the prosthetic set-up, to avoid major surgical procedure [11]. To overcome this drawback, conversion of internal conical connections is always mandatory to ensure accurate fitting of the prosthetic framework. According to recent systematic reviews, misfit and microleakage at the implant abutment interface may create biological and technical problems, favoring the onset of peri-implant diseases [12]. In addition to the platform conversion, abutment-level restoration may reduce soft tissue inflammation, patient discomfort, and, finally, the peri-implant marginal bone loss [13–15]. Today, multi abutments are widely used to convert the implant connections. In recent years, novel narrow and low-profile abutments were proposed for screw-retained, implant-support fixed restorations, delivered at abutment level [16,17]. The same abutments were already successfully used in dentistry to retain implant overdentures [18,19].

The aim of the present multicenter retrospective study is to report preliminary data on survival and success rates of immediately loaded, screw-retained, implant-supported restorations delivered on lower arches using novel narrow and low-profile OT Equator abutments, according to the OT Bridge prosthetic protocol.

2. Materials and Methods

This study was designed as multicenter, retrospective, case series study written according to the STROBE guidelines. Patients were recruited and treated in five centers in Italy and Albania (M.M.; R.S.; M.P.; E.F.; and M.T.). A chart review of previously treated patients received immediately loaded, mandible, screw-retained, implant-supported restorations, delivered on novel narrow and low-profile OT Equator abutments (Rhein'83) were performed by an independent examiner (G.C.). All the treatments were performed from November 2017 to February 2019. A written informed consent

for surgical and prosthetic procedures including clinical and radiological data, were obtained from each patient. This research adhered to the principles embodied in the Helsinki Declaration of 2013. Medical data was anonymized so that patients cannot be identified. The study protocol was approved by the Ethics Committee of Aldent University in Tirana (Protocol n° 4/2020).

After accurate evaluation of available documents, radiographs, and pictures, all screened patients were included or excluded according to pre-established inclusion/exclusion criteria (Table 1).

Table 1. Inclusion and exclusion criteria.

Inclusion Criteria	Exclusion Criteria
Aged 18 years or older	General contraindications for oral surgery
Signed informed consent	Heavy smokers (≥ 11 cigarettes per day)
OT Bridge in the mandible arch	Poor oral hygiene (Bleeding on Probing $> 25\%$)
Screw-retained prosthetic retention	Local acute or chronic infections
One-year after loading follow-up (FU)	Substance abuse (drugs or alcohol)
Available radiographs (implant loading and 1-year FU)	Psychiatric problems
	Pregnancy or breastfeeding
	Treatment with intravenous bisphosphonates
	Irradiation of the neck or head area in the past 5 years
	Absence of teeth in the opposite arch
	Severe bruxism or jaw clenching

All patients received prophylactic antibiotic therapy: 2 g of amoxicillin (or clindamycin 600 mg if allergic to penicillin) 1 h before the intervention and rinsed with chlorhexidine mouthwash 0.2% for one minute prior to the intervention. The implants were placed with a surgical guide template, under local anesthesia (articaine with adrenaline 1:100,000), and according to the manufacturer's instructions. All the implants were planned as parallel as possible, avoiding bone reconstruction procedures. All the implants were placed with an insertion torque ranging between 25 and 45 Ncm. Immediately after implant placement, narrow- and low-profile OT Equator abutments (Rhein'83, Bologna, Italy) were screwed onto the implants according to the manufacturer and in agreement with the one-abutment at one-time concept (Figure 1). The transmucosal height of the abutments was chosen based on the soft tissue thickness and implant depth. Afterwards, cylindric "extragrade" abutments (Figure 2, Rhein'83) were screwed onto the OT Equator (Rhein'83) and the pre-fabricated, acrylic temporary restoration rebased, according to an immediate loading protocol. In cases where immediate temporary restoration was not planned, screwed healing abutments (Rhein'83) were connected during the healing period (eight to twelve weeks). All patients received a drug prescription consisting on antibiotic therapy for five days and ibuprofen 600 mg as needed. Moreover, oral and written recommendations were given about the correct oral hygiene maintenance (including 0.2% chlorhexidine mouthwash for a minute, twice a day for two weeks) and patients were recommended to have a soft diet for one month. Between 8 and 12 weeks later, definitive, abutment-level impressions were made according to a previously published protocol [20], and screw-retained, CAD/CAM (Figures 3 and 4), titanium-composite restorations were delivered (Figures 5 and 6). Before screwing, the acetal rings (Seeger system, Rhein'83) were inserted into the frameworks' connections that allow the retention to the sub-equatorial area of the OT Equator's snap-on function. The fit was accurately checked [21]. The prostheses were screwed twice at 20 Ncm, with a 10 min break. Occlusion was adjusted and patients were enrolled in a strictly follow-up protocol including occlusal adjustment and hygiene maintenance every 6 months, and radiographs every year.

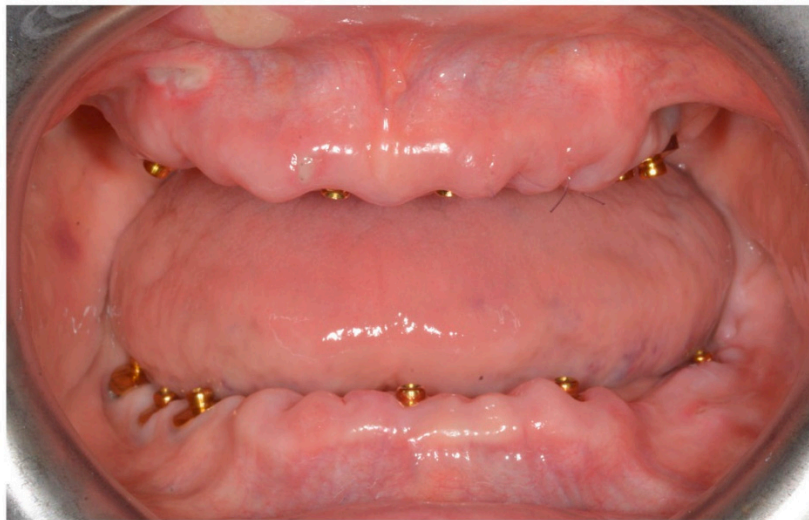

Figure 1. OT Equator screws on implant at the time of surgery according to one-time one-abutment.

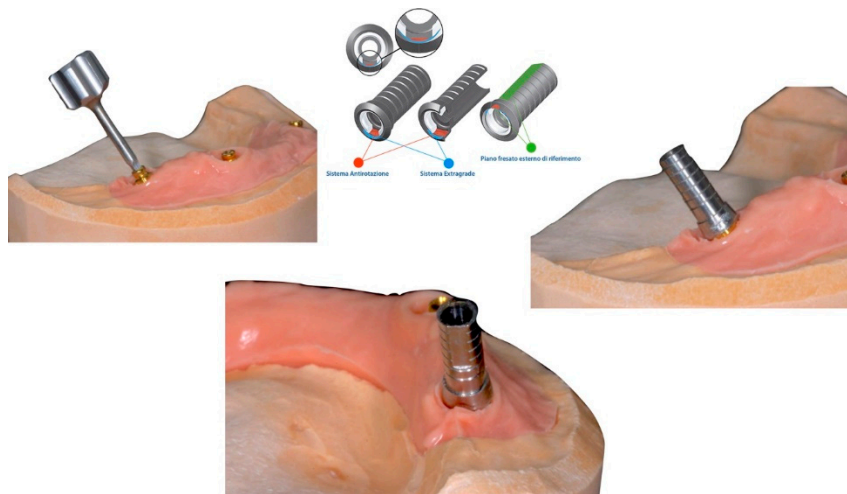


Figure 2. The extragrade abutment system for OT Bridge to allow strong divergences among implants.

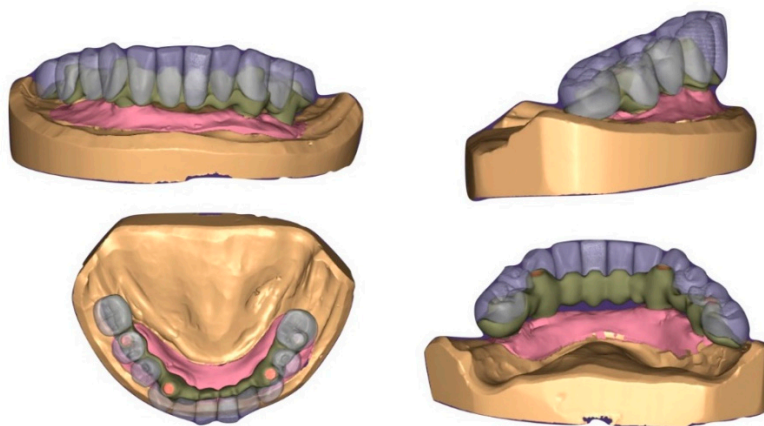


Figure 3. CAD/CAM steps for OT Bridge.

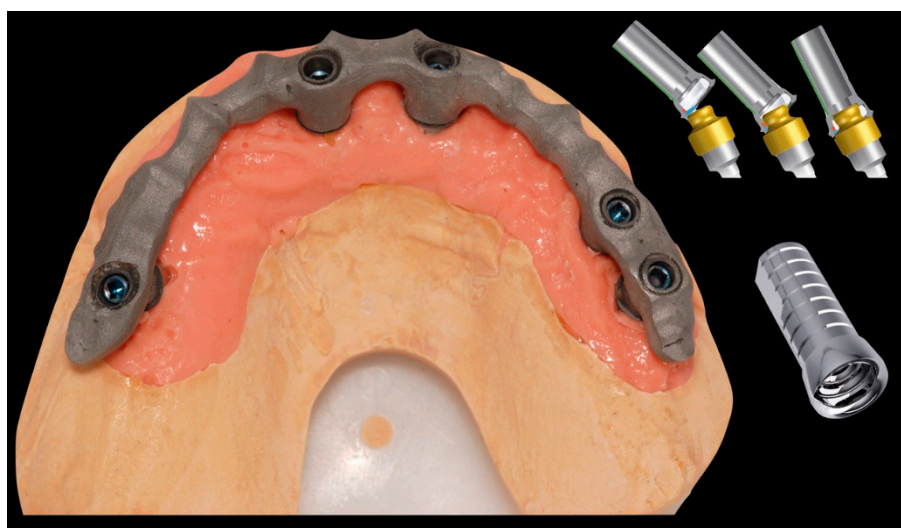


Figure 4. Lost wax technique to realize hybrid prosthetic.

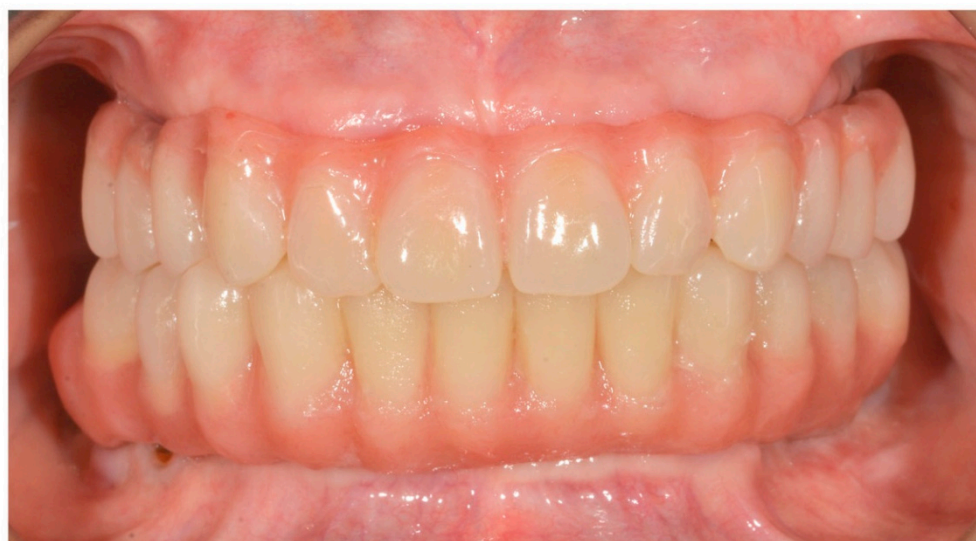

Figure 5. Immediate loading with OT Bridge system.

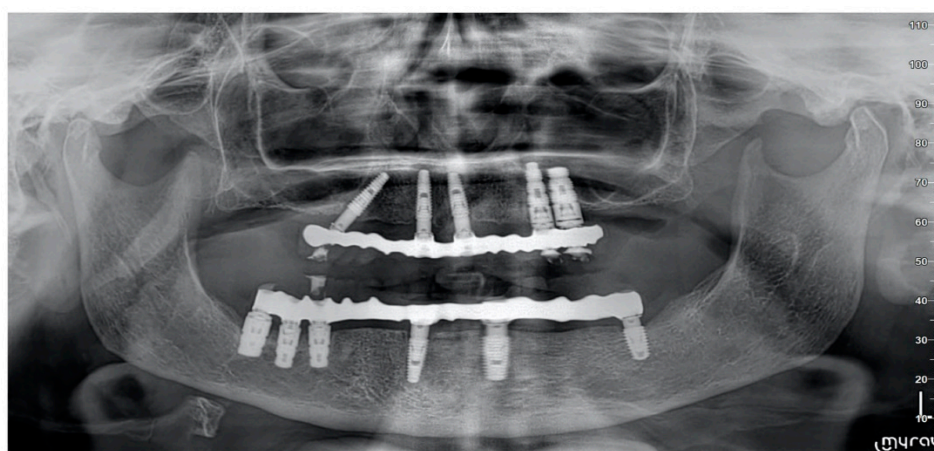


Figure 6. Rx opt with OT Equator screws on implants and OT Bridge system.

The primary outcomes measures were the implant and prosthetic failure, and any technical or biological complications.

- Implant failure was defined as mobility, infection, fracture, and/or any other mechanical or biological issue that determined its removal.
- A prosthesis was considered a failure any time it had to be replaced.
- Any biological (e.g., drug-resistant pain, swelling, excessive marginal bone loss, suppuration, etc.) and/or technical (e.g., fracture of the veneering material and or framework, screw loosening, etc.) complications were recorded during follow-up.

Secondary outcome measures were marginal bone level changes, periodontal parameters, and patient satisfaction.

- Marginal bone levels were measured as the distance between the implant platform to the first bone to implant contact. Mean values of mesial and distal measurements were calculated for each implant. Marginal bone level was measured on digital periapical radiographic images obtained by parallel technique with Rinn's film holder (Rinn XCP, Dentsply, Elgin, IL, USA) taken at definitive implant loading (baseline) and then one year after. All radiographs were analyzed through a dedicate software (DFW2.8 for Windows, Soredex, Tuuka, Finland), calibrated for each image using the known distance between two consecutive threads. The difference between baseline and last follow-up was taken as marginal bone loss. One dentist at each center, not previously involved in this study, performed every radiographic measurement.
- Bleeding index and plaque index were evaluated in six sites around each implant–abutment interface at the one-year examination with a periodontal probe (PCPUNC156, Hu-Friedy, Milan, Italy). One dental hygienist at each center, not previously involved in this study, performed the periodontal measurements
- Oral Health Impact Profile (OHIP-21) was calculated with a questionnaire of 21 questions, divided in seven subscales (functional limitations, physical pain, psychological discomfort, physical disability, psychological disability, social disability, and handicap), consisting of two to four questions each, filled out by patients. Patients were instructed to choose between five possible responses ranging from 1 (never) to 5 (very often). The questionnaire was administered by an independent dentist before treatment and one year after definitive prosthesis delivery.

3. Statistical Analysis

Based on the authors' knowledge, there are no similar in vivo studies that evaluated clinical performance of OT Bridge concept in the mandible. Therefore, an a priori sample size calculation was not performed. In the present retrospective study, the authors decided to collect as much cases as possible. The differences between these two groups were compared with Fisher exact test for dichotomous outcomes (complications between sub-groups, such as smokers and immediately loaded implants) and with Mann-Whitney U tests for continuous variables (HOIP, marginal bone levels between baseline and 1 year after loading). All analyses were conducted at the 0.05 level of significance. Statistical analysis was performed by software (SPSS for Mac OS X v22.0, Chicago, IL, USA).

4. Results

Out of 28 medical records from five centers, 12 patients (6 women, 6 men; range 39–77 years old; average age 63.2 ± 11.7 years) were selected according to inclusion and exclusion criteria. Of 16 excluded patients, two did not reach the 1 year follow-up, and 14 received maxilla restoration. A total of 60 implants were inserted (range 4–7; average 6.1 for each patient). Five patients were light smokers. Only one patient presented one controlled systemic disease (73 years old male with diabetes). All patients were class two or three of Cawood and Howell. All patients were followed for at least 1 year after definitive prosthesis delivery (range 12–28 months; average follow-up 19.5 ± 6.1 months).

Seven patients (with 37 implants) received a temporary restoration the same day of surgery (immediate loading), while five patients (23 implants) received the temporary restoration from eight to twelve weeks later, according to an early loading protocol (Figures 5 and 6). Four out of 60 implants (6.7%) were connected to the prosthetic framework using only the Seeger system, without any screw. In five patients, the antagonist was a complete removable denture, setting a bilateral balanced occlusion. In the other seven cases, natural teeth or implants there were in the antagonist arch, setting an occlusion with anterior guidance ($n = 1$) or group function (unilateral balanced occlusion, $n = 6$). One year after loading, three implants failed (implant survival rate of 95.0%) in two patients. Two of these failed in a no smoker patient, while, the other implants failed in a smoker patient. The difference was not significant ($p = 0.576$). Regarding loading protocol, all the implants failed when immediate loading protocol was applied. Nevertheless, the difference was not significant ($p = 0.279$). None of the definitive prosthesis failed (survival rate of 100%). No prosthetic complications were experienced. Nevertheless, in all the failed implants cases, the temporary restorations were adapted on the remaining implants during the healing phase, and new implants were inserted.

Marginal bone level at implant placement was 0.05 ± 0.07 mm. One year after initial loading, the marginal bone level was 0.32 ± 0.2 . The difference was statistically significant (0.27 ± 0.14 mm; $p = 0.0001$). One year after loading, 8.9% of the examined implant sites presented positive bleeding on probing, while, 5.8% of the implant sites presented plaque. The OHIP before treatment was 87.7 ± 6.0 . One year after treatment, OHIP was 23.6 ± 1.2 . The difference was statistically significant (64.1 ± 7.2 ; $p = 0.0000$) (Table 2).

Table 2. Main mean results.

	Implant Placement (mm)	1-Year After Loading (mm)	Difference (mm)
Marginal bone	0.05 ± 0.07	0.32 ± 0.2	0.27 ± 0.14
Bleeding on probing		8.9%	
		5.8%	
	87.7 ± 6.00	23.6 ± 1.2	64.1 ± 7.2

5. Discussion

The present multicenter retrospective study was conducted to evaluate the performance of the OT Equator system (Rhein'83) used to support a screw-retained fixed dental prosthesis delivered in complete edentulous lower arches. To the best of the authors' knowledge, no other studies in the literature have aimed to analyze OT Equator with OT Bridge in fixed dental prosthesis in mandible. High implant and prosthesis survival rates were experienced after one year of function. One year after initial loading the marginal bone level was 0.32 ± 0.2 mm. Compared to the baseline, the difference was 0.27 ± 0.14 mm. This value agrees with studies evaluating a one-abutment one-time concept, showing good benefits of this prosthetic protocol [4]. The opportunity to screw the low-profile attachments immediately after placement of the implants, without removing them during the prosthetic phases, represents a significant biological advantage because it avoids possible damages of the epithelial ligaments and the connective fibers that grow circumferentially around the titanium neck of the abutment [4]. These epithelial fibers are the biological seal and play a vital role in preventing infections of the deep tissues. Moreover, at this stage, the OT Equator abutments (Rhein'83) can be used as direct retentive attachments in order to improve the stability of the provisional prosthesis. Finally, the OT Equator system with its height [22] and small diameter allows for a platform switching concept [13–15] helping to reduce the overall amount of peri-implant bone remodeling. The characteristics (thin-shaped and parallel-wall abutment) of the OT Equators (Rhein'83) are responsible for the increasing mismatch between implant and abutment diameter. These features permit us to increase the space for the soft tissue. These two characteristics seem to be responsible for the good biological parameters over time.

In the present study, no prosthetic complications were experienced and the marginal bone loss after one year of function was (0.27 ± 0.14 mm). Similar results were obtained when evaluating the same OT Bridge system (Rhein'83) to support immediately loaded maxillary fixed restorations [23]. The authors experienced only one prosthetic complication, and the marginal bone loss was 0.21 ± 0.11 mm.

When restoring a complete edentulous arch with a screwed implant prosthesis, even with a minimal disparallelism between the implants, the use of intermediate abutments is highly recommended. Abutments placed at implant insertion and never removed also allow us to reduce the amount of peri-implant marginal bone remodeling [4]. Multi-unit abutments are designed with a range of angle correction and an external conical connection that allows to provide a passive prosthesis fit. The main limitations of the multi-unit abutments are its wide diameter, but also the weak secondary screw. Nevertheless, due to the great biological and functional benefits, its use is highly recommended [5]. In recent years, the OT Equator attachment (Rhein'83) has been proposed as an alternative to the multi-unit abutment in partial and complete edentulous arches. The OT Equator attachment (Rhein'83) seems to be a global, well-established system used in the removable prosthetic protocols for several years [1,17–19]. Thanks to its features and great versatility, OT Equator can be used to support a screw-retained fixed dental prosthesis [17]. Moreover, the Seeger system, represents a novel and revolutionary acetal ring placed between the sub-equatorial area of the OT Equator and the cylindrical “extragrade” abutment. When two or more implants are connected together, a possible problem is that a poor passivity of the framework can transmit the tensions to the implants leading at first to an incorrect connection of the prosthesis and then to an implant failure. In the present study, the passivity of the framework was obtained by the Elastic Seeger that is able to compensate the space between the “extragrade” abutment and the OT Equator. The tolerance between the “extragrade” abutment and the OT Equator has been designed to compensate for minor misalignments that can be produced during the impression and the pouring of the cast model [24]. This innovative concept also allows us to reduce the number of screws needed to support the prosthesis [17]. Usually, 1 to 2 screws can be avoided in the case of 4 to 6 placed implants respectively, and preferably, within screwed ones [23]. In fact, in a recent publication on fixed complete arches restorations, 3 out of 76 implants were connected to the prosthetic framework using only the Seeger system, without a screw when the OT Bridge system (Rhein'83) was used [23]. This is an important feature in the aesthetics zone when implants were not placed in a prosthetic way [17]. Another benefit of the OT Equator system is its ability to overcome high implant divergency, even in extreme cases over 80° . The OT Equator system is also available as a public library in most professional CAD software, allowing for digital workflows [25–28] and planning in advance of the prosthetically-driven implant-supported rehabilitations.

The main limitations of the present research are the short follow-up, the small sample size, and the lack of a control group. Nevertheless, this research was designed as proof-of-concept study aimed to evaluate preliminary data on the survival and success rates of immediately loaded, screw-retained, restorations delivered on lower arches using OT Equator abutments. Further and larger studies are needed to confirm this preliminary data.

6. Conclusions

Within the limitations of this study, the OT Bridge system showed successful results when used to support a fixed dental prosthesis in complete edentulous lower arches screwed on four to seven implants with OT Equator as abutment and the Seeger system. High implant and prosthetic survival rates, very low complications, high patient satisfaction, and good biological parameters could be expected after one year of function. The possibility not to use one or two screws on abutments if the emergency profile of implant is hard to handle could be a great function of this system. However, further randomized controlled trials with larger sample size are needed to confirm these preliminary results.

Author Contributions: Conceptualization, M.T.; methodology, R.S.; writing—original draft preparation, M.M.; writing—review and editing, M.P.; visualization, E.F.; supervision, G.C.; E.X.; A.K.; All authors have read and agreed to the published version of the manuscript.

Funding: This research received no external funding.

Conflicts of Interest: The authors declare no conflict of interest.

References

1. Scrasecia, R.; Fiorillo, L.; Gaita, V.; Secondo, L.; Nicita, F.; Cervino, G. Implant-Supported Prosthesis for Edentulous Patient Rehabilitation. From Temporary Prosthesis to Definitive with a New Protocol: A Single Case Report. *Prosthesis* **2020**, *2*, 10–24. [\[CrossRef\]](#)
2. Pozzi, A.; Tallarico, M.; Moy, P. Four-implant overdenture fully supported by a CAD-CAM titanium bar: A single-cohort prospective 1-year preliminary study. *J. Prosthet. Dent.* **2016**, *116*, 516–523. [\[CrossRef\]](#)
3. Tallarico, M.; Meloni, S.; Canullo, L.; Caneva, M.; Polizzi, G. Five-Year Results of a Randomized Controlled Trial Comparing Patients Rehabilitated with Immediately Loaded Maxillary Cross-Arch Fixed Dental Prosthesis Supported by Four or Six Implants Placed Using Guided Surgery. *Clin. Implant Dent. Relat. Res.* **2016**, *18*, 965–972. [\[CrossRef\]](#)
4. Tallarico, M.; Caneva, M.; Meloni, S.; Xhanari, E.; Covani, U.; Canullo, L. Definitive Abutments Placed at Implant Insertion and Never Removed: Is It an Effective Approach? A Systematic Review and Meta-Analysis of Randomized Controlled Trials. *J. Oral Maxillofac. Surg.* **2018**, *76*, 316–324. [\[CrossRef\]](#) [\[PubMed\]](#)
5. Tallarico, M.; Caneva, M.; Baldini, N.; Gatti, F.; Duvina, M.; Billi, M.; Iannello, G.; Piacentini, G.; Meloni, S.M.; Cicciù, M. Patient-centered rehabilitation of single, partial, and complete edentulism with cemented- or screw-retained fixed dental prosthesis: The First Osstem Advanced Dental Implant Research and Education Center Consensus Conference 2017. *Eur. J. Dent.* **2018**, *12*, 617. [\[CrossRef\]](#) [\[PubMed\]](#)
6. Tallarico, M.; Esposito, M.; Xhanari, E.; Caneva, M.; Meloni, S.M. Computer-guided vs free-hand placement of immediately loaded dental implants: 5-year postloading results of a randomised controlled trial. *Eur. J. Oral Implant.* **2018**, *11*, 203–213.
7. Tallarico, M.; Meloni, S. Retrospective Analysis on Survival Rate, Template-Related Complications, and Prevalence of Peri-implantitis of 694 Anodized Implants Placed Using Computer-Guided Surgery: Results Between 1 and 10 Years of Follow-Up. *Int. J. Oral Maxillofac. Implant.* **2017**, *32*, 1162–1171. [\[CrossRef\]](#)
8. Tallarico, M.; Meloni, S.M.; Canullo, L.; Xhanari, E.; Polizzi, G. Guided surgery for single-implant placement: A critical review. *J. Oral Sci. Rehabil.* **2016**, *2*, 8–14.
9. Tallarico, M.; Martinolli, M.; Kim, Y.-J.; Cocchi, F.; Meloni, S.M.; Alushi, A.; Xhanari, E. Accuracy of Computer-Assisted Template-Based Implant Placement Using Two Different Surgical Templates Designed with or without Metallic Sleeves: A Randomized Controlled Trial. *Dent. J.* **2019**, *7*, 41. [\[CrossRef\]](#)
10. Tallarico, M.; Kim, Y.-J.; Cocchi, F.; Martinolli, M.; Meloni, S.M. Accuracy of newly developed sleeve-designed templates for insertion of dental implants: A prospective multicenters clinical trial. *Clin. Implant. Dent. Relat. Res.* **2019**, *21*, 108–113. [\[CrossRef\]](#)
11. Tallarico, M.; Ceruso, F.; Xhanari, E.; Gargari, M.; Canullo, L.; Meloni, S. Immediately loaded tilted implants combined with angulated screw channel zirconia abutments in atrophic maxillary patients: A three-year after loading prospective case series study. *ORAL Implantol.* **2018**, *11*, 106–114.
12. Tallarico, M.; Fiorellini, J.; Nakajima, Y.; Omori, Y.; Takeshi, I.; Canullo, L. Mechanical Outcomes, Microleakage, and Marginal Accuracy at the Implant-Abutment Interface of Original versus Nonoriginal Implant Abutments: A Systematic Review of In Vitro Studies. *BioMed Res. Int.* **2018**, *2018*, 2958982. [\[CrossRef\]](#)
13. Pozzi, A.; Tallarico, M.; Moy, P.K. Three-year post-loading results of a randomised, controlled, split-mouth trial comparing implants with different prosthetic interfaces and design in partially posterior edentulous mandibles. *Eur. J. Oral Implant.* **2014**, *7*, 47–61.
14. Pozzi, A.; Agliardi, E.; Tallarico, M.; Barlattani, A. Clinical and Radiological Outcomes of Two Implants with Different Prosthetic Interfaces and Neck Configurations: Randomized, Controlled, Split-Mouth Clinical Trial. *Clin. Implant. Dent. Relat. Res.* **2014**, *16*, 96–106. [\[CrossRef\]](#)
15. Meloni, S.M.; Lumbau, A.; Baldoni, E.; Pisano, M.; Spano, G.; Massarelli, O.; Tallarico, M. Platform switching versus regular platform single implants: 5-year post-loading results from a randomised controlled trial. *Int. J. Oral Implantol.* **2020**, *13*, 43–52.
16. Meloni, S.M.; Tallarico, M.; Pisano, M.; Xhanari, E.; Canullo, L. Immediate Loading of Fixed Complete Denture Prosthesis Supported by 4–8 Implants Placed Using Guided Surgery: A 5-Year Prospective Study on 66 Patients with 356 Implants. *Clin. Implant. Dent. Relat. Res.* **2017**, *19*, 195–206. [\[CrossRef\]](#)

17. Tallarico, M.; Scrascia, R.; Annucci, M.; Meloni, S.M.; Lumbau, A.I.; Koshovari, A.; Xhanari, E.; Martinolli, M. Errors in Implant Positioning Due to Lack of Planning: A Clinical Case Report of New Prosthetic Materials and Solutions. *Materials* **2020**, *13*, 1883. [\[CrossRef\]](#)
18. Xhanari, E.; Scrascia, R.; Kadiu, B.; Tallarico, M. Two implants supporting a mandibular over-denture to rehabilitate Cawood and Howell Class V and VI patients: A proof-of-concept study. *J. Oral Sci. Rehabil.* **2017**, *3*, 52–59.
19. Tallarico, M.; Ortensi, L.; Martinolli, M.; Casucci, A.; Ferrari, E.; Malaguti, G.; Montanari, M.; Scrascia, R.; Vaccaro, G.; Venezia, P.; et al. Multicenter Retrospective Analysis of Implant Overdentures Delivered with Different Design and Attachment Systems: Results Between One and 17 Years of Follow-Up. *Dent. J.* **2018**, *6*, 71. [\[CrossRef\]](#)
20. Pozzi, A.; Tallarico, M.; Mangani, F.; Barlattani, A. Different implant impression techniques for edentulous patients treated with CAD/CAM complete-arch prostheses: A randomised controlled trial reporting data at 3 year post-loading. *Eur. J. Oral Implant.* **2013**, *6*, 325–340.
21. Abduo, J.; Bennani, V.; Waddell, N.; Lyons, K.; Swain, M. Assessing the fit of implant fixed prostheses: A critical review. *Int. J. Oral Maxillofac. Implant.* **2010**, *25*, 506–515.
22. Galindo-Moreno, P.; Leon-Cano, A.; Monje, A.; Ortega-Oller, I.; O'Valle, F.; Catena, A. Abutment height influences the effect of platform switching on peri-implant marginal bone loss. *Clin. Oral Implant. Res.* **2016**, *27*, 167–173. [\[CrossRef\]](#)
23. Acampora, R.; Montanari, M.; Scrascia, R.; Ferrari, E.; Pasi, M.; Cervino, G.; Meloni, S.; Lumbau, A.; Erta, X.; Koshovari, A.; et al. 1-Year Evaluation of OT Bridge Abutments for Immediately Loaded Maxillary Fixed Restorations: A Multicenter Study. *Eur. J. Dent.* **2020**. Ahead of Print. [\[CrossRef\]](#)
24. Montanari, M.; Bonato, G.; Ortensi, L. Oral Rehabilitation with Implant-Supported Overdenture and a New Protocol for Bar Passivation. *Global J. Oral Sci.* **2016**, *2*, 10–19.
25. Cervino, G.; Cicciù, M.; Fedi, S.; Milone, D.; Fiorillo, L. FEM Analysis Applied to OT Bridge Abutment with Seeger Retention System. *Eur. J. Dent.* **2020**. Epub Ahead of Print, PMID: 32869222. [\[CrossRef\]](#)
26. Ceruti, P.; Mobilio, N.; Bellia, E.; Borracchini, A.; Catapano, S.; Gassino, G. Simplified edentulous treatment: A multicenter randomized controlled trial to evaluate the timing and clinical outcomes of the technique. *J. Prosthet. Dent.* **2017**, *118*, 462–467. [\[CrossRef\]](#)
27. Mobilio, N.; Catapano, S. The use of monolithic lithium disilicate for posterior screw-retained implant crowns. *J. Prosthet. Dent.* **2017**, *118*, 703–705. [\[CrossRef\]](#)
28. Mobilio, N.; Fasiol, A.; Catapano, S. Survival Rates of Lithium Disilicate Single Restorations: A Retrospective Study. *Int. J. Prosthodont.* **2018**, *31*, 283–286. [\[CrossRef\]](#)

Publisher's Note: MDPI stays neutral with regard to jurisdictional claims in published maps and institutional affiliations.



© 2020 by the authors. Licensee MDPI, Basel, Switzerland. This article is an open access article distributed under the terms and conditions of the Creative Commons Attribution (CC BY) license (<http://creativecommons.org/licenses/by/4.0/>).