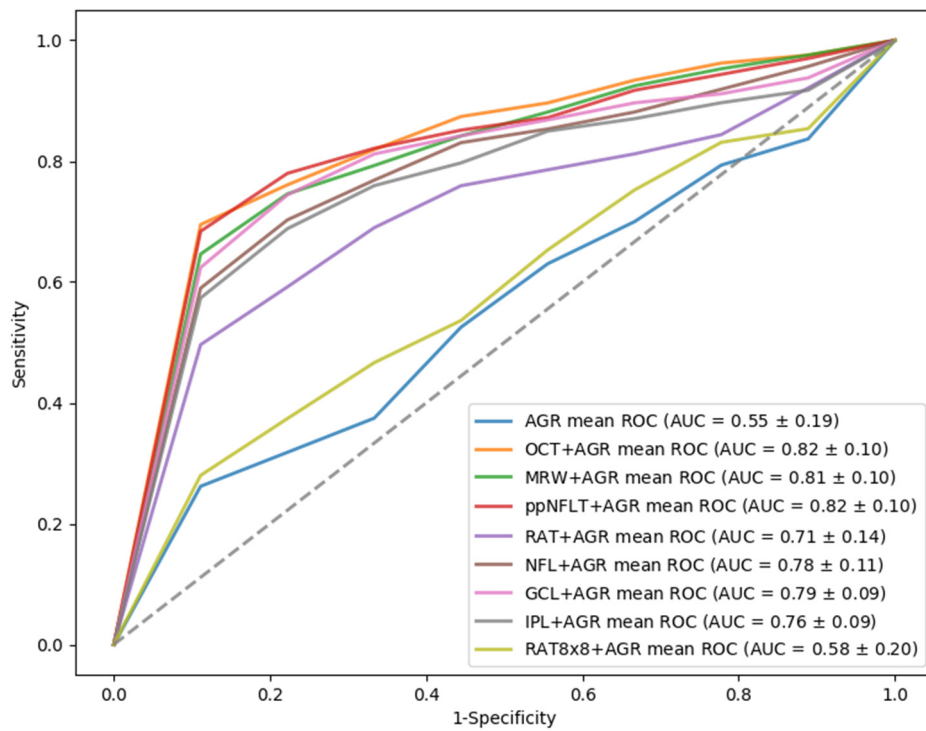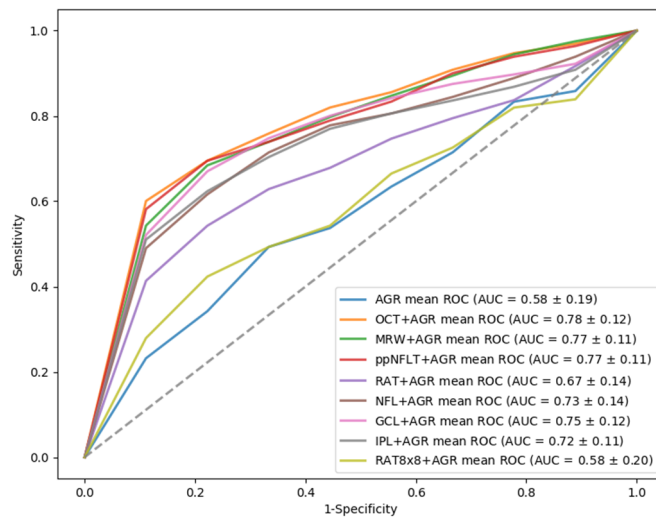
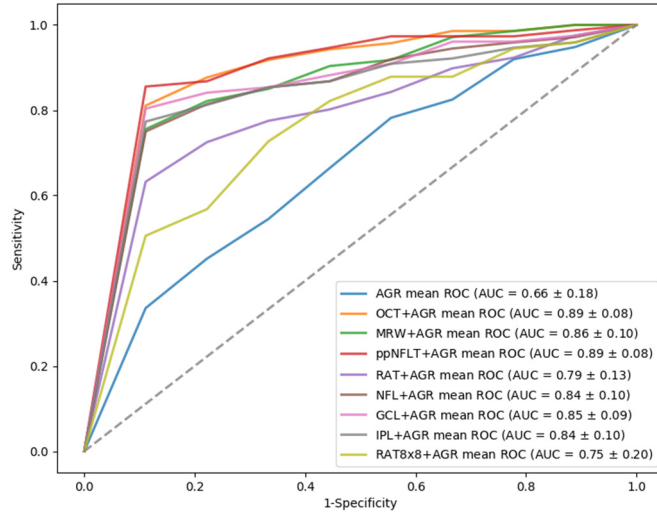


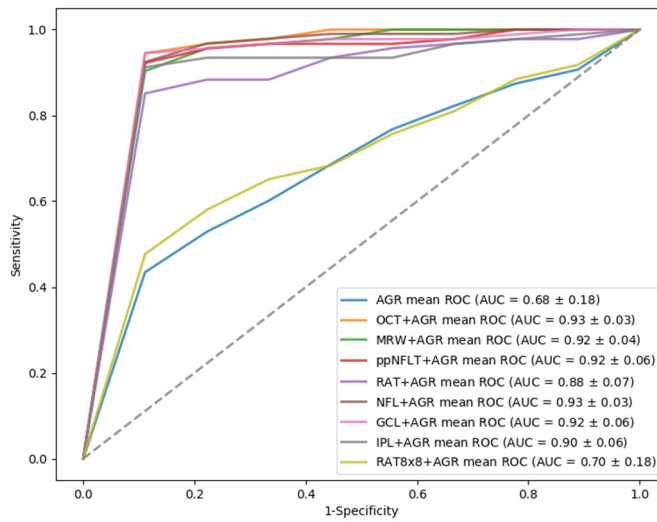
Figure S1. Receiver operating characteristic (ROC) curve of optical coherence tomography (OCT)-related features groups plus age, gender and refraction in differentiating normal from glaucomatous eyes



(a)



(b)



(c)

Figure S2. Receiver of characteristic (ROC) curve of optical coherence tomography (OCT)-related features groups plus age, gender and refraction in differentiating normal from (a) early, (b) moderate, and (c) severe glaucomatous eyes